

Université de Montréal

# **Evaluation of a novel transcortical pin-sleeve system in a calf model**

par

Susan R. Vogel

Département de sciences cliniques

Faculté de médecine vétérinaire

Mémoire présenté à la Faculté de médecine vétérinaire  
en vue de l'obtention du grade de maîtrise ès science (M.Sc.)

en sciences vétérinaires

option sciences cliniques

Avril 2011

© Susan R. Vogel, 2011

Université de Montréal  
Faculté de médecine vétérinaire

Ce mémoire intitulé

Evaluation of a novel transcortical pin-sleeve system in a calf model

Présentée par :  
Susan R. Vogel

a été évalué par un jury composé des personnes suivantes

Yvone Elce, présidente-rapporteuse  
André Desrochers, codirecteur de recherche  
Ludovic Bouré, codirecteur de recherche  
Bertrand Lussier, membre du jury

## Résumé

Le desserrage des tiges est une complication fréquente des plâtres avec tiges transcorticales (TP) chez les grands animaux, nécessitant souvent leur retrait prématuré avant la guérison des fractures. Les charges excessives centrées sur le cortex à l'interface os-tige proximo-externe et disto-interne causent de l'ostéolyse. En utilisant un modèle de veau nouveau-né, ce projet a évalué un nouveau système de tige-manchon et anneau intégré dans un plâtre (PS) optimisé pour réduire la contrainte péri-implant et le stress à l'interface os-implant. On a émis l'hypothèse que les PS se traduiraient par une ostéolyse péri-implant moindre par rapport aux TP.

Dix veaux en bonne santé, de 3 semaines d'âge, ont été implantés avec les TP ou PS dans le métacarpe droit, à raison de 2 implants par veau. Les veaux ont été observés quotidiennement pour le confort et la boiterie et ont été euthanasiés à 28 jours. Les données recueillies comprenaient les radiographies à la chirurgie et à l'euthanasie et les mesures histomorphométriques de contact os-implant sur des échantillons non-décalcifiés avec les implants *in situ*. Les données ont été analysées en utilisant le test de Cochran-Mantel-Haenszel, une valeur de  $P < 0,05$  a été considéré comme significative.

L'épaisseur corticale était plus importante pour les implants distaux que proximaux pour les deux groupes lors de la chirurgie ( $P = 0,03$ ), mais était similaire entre les groupes ( $P > 0,3$ ). Les veaux avec TP ont développé une boiterie plus tôt (au jour 21) que les veaux avec PS ( $P = 0,04$ ). Histologiquement, il y avait plus de contact direct os-implant cortical pour les implants PS distaux que les implants TP ( $P = 0,04$ ).

La jonction métaphyso-diaphysaire osseuse où les implants proximaux étaient situés est impropre aux deux systèmes; chacun a un minimum de contact os-implant et de l'ostéolyse extensive. Le système PS n'ayant pas causé une ostéolyse importante lorsque implantés dans l'os diaphysaire et peut-être une alternative convenable aux TP pour des fractures comminutives des membres distaux.

**Mots-clés** : plâtres, tiges transcorticales, ostéolyse péri-implant, fixateur externe, veau

## Abstract

Pin loosening is a common complication of transfixation pincasts (TP) in large animals, often necessitating premature removal before fracture healing. The excessive loads centered on the proximo-external and disto-internal cortices of the bone-pin interface cause osteolysis. Using a neonatal calf model, this project evaluated a novel pin-sleeve and ring cast system (PS) optimized to decrease peri-implant strain and evenly share stress at the bone-implant interface. It was hypothesized that PS would result in less peri-implant osteolysis compared to TP.

Ten, 3-week-old, healthy calves were implanted with either TP or PS in the right metacarpus, 2 implants per calf. Calves were scored daily for lameness and were euthanized at day 28. Collected data included radiographs at surgery and euthanasia and histomorphometric measures of bone-implant contact on non-decalcified specimens with the implants in situ. Data was analyzed using Cochran-Mantel-Haenszel test; a P-value  $<.05$  was considered significant.

The cortical thickness was larger for distal implants than proximal implants for both groups at surgery ( $P = 0.03$ ), but were similar between groups ( $P > 0.3$ ). TP calves developed lameness sooner, at day 21, than PS calves ( $P = 0.04$ ). Histologically, there was more direct cortical bone-implant contact for PS distal implants than TP implants ( $P = 0.04$ ).

The metaphyseal-diaphyseal junction where the proximal implants were situated is unsuitable bone for either system; each had minimal bone-implant contact and extensive osteolysis. The PS system did not cause significant osteolysis when instrumented in diaphyseal bone and is a suitable alternative to TP for comminuted distal limb fractures.

**Keywords** : transfixation pin cast, peri-implant osteolysis, external skeletal fixation, calf model

## Table of Contents

INTRODUCTION.....	1
LITERATURE REVIEW.....	4
1. External Skeletal fixation.....	4
1.1 ESF specific to large animals.....	4
1.2 Optimization of ESF configurations.....	6
1.3 Complications associated with transcortical pins.....	8
1.3.1 Implant infection.....	9
1.3.2 Implant loosening.....	10
1.3.2.1 Biomechanical considerations of implant loosening.....	10
1.3.2.2 Clinical reports of implant loosening.....	12
1.3.2.3 Attempts to prevent implant loosening.....	13
1.3.3 Implant and bone failure.....	16
1.3.4 Cast complications.....	16
2. The pin-sleeve cast.....	17
2.1 Description of the PS system.....	17
2.2 Biomechanical properties of PS vs. TP.....	18
2.2.1 Bone substitute model.....	18
2.2.2 Finite element analysis.....	19
2.3 PS system scaled-down for clinical trial in calves.....	19
3. Calves as a model for implant loosening.....	23
3.1 Physical properties of neonatal calf bone.....	24
3.2 Measurements of bone strength in neonatal calves.....	24
3.3 Neonatal calves as a model for implant loosening.....	25
ARTICLE.....	26
Abstract.....	27
Introduction.....	28
Materials and Methods.....	30

Results .....	36
Discussion .....	45
References .....	50
Footnotes .....	54
DISCUSSION .....	55
CONCLUSION .....	64
BIBLIOGRAPHY .....	65
APPENDIX A: PILOT STUDY .....	<i>i</i>
APPENDIX B: STATIC FORCE PLATE .....	<i>iv</i>
APPENDIX C: SURGICAL INSTRUMENTATION AND TECHNIQUES .....	<i>vii</i>

## List of tables

Table I: Data from <i>in vitro</i> and <i>ex vivo</i> PS vs. TP testing.....	21
Table II: Pain score chart .....	31
Table III: Radiographic and histomorphometric data .....	37
Table IV: Static force plate data, Appendix A .....	v



## List of figures

Figure 1: Diagram of pin bending with type I.A and II ESF .....	11
Figure 2: Diagram of taper sleeve system with type II ESF .....	15
Figure 3: Diagram of pin bending in novel PS system .....	18
Figure 4: Photographs of the PS system .....	20
Figure 5: Woven bone.....	22
Figure 6: Cortical bone.....	23
Figure 7: Cancellous bone.....	23
Figure 8: Photograph of the neonatal PS system .....	30
Figure 9: Labeled cortices for data collection.....	34
Figure 10: Photographs of skin healing .....	38
Figure 11.a: Histology of proximal TP implant.....	39
Figure 11.b: Histology of distal TP implant.....	40
Figure 12.a: Histology of proximal PS implant .....	41
Figure 12.b: Histology of distal PS implant.....	42
Figure 13.a: Radiographs of calf euthanized at day 18.....	43
Figure 13.b: Histology of calf euthanized at day 18 .....	44
Figure 14: Pilot study radiographs of TP, Appendix A .....	<i>ii</i>
Figure 15: Pilot study radiographs of PS, Appendix A.....	<i>iii</i>
Figure 16: Static force plate graphic, Appendix B.....	<i>vi</i>
Figure 17: Surgery table for a PS surgery, Appendix C .....	<i>vii</i>
Figure 18: Needle placement .....	<i>viii</i>
Figure 19: Drill guide with sleeve, Appendix C .....	<i>ix</i>
Figure 20: Hand insertion of sleeve, Appendix C.....	<i>x</i>
Figure 21: Inserted sleeve .....	<i>xi</i>
Figure 22: PS assembly in a pilot calf, Appendix C .....	<i>xii</i>
Figure 23: Cast application for PS pilot calf.....	<i>xiii</i>
Figure 24: PS calf 4 hours post-op.....	<i>xiv</i>

*This project was completed with support from the AO foundation, Pfizer research funds and fonds du centenaire. I am grateful to Drs. Sylvain Nichols, Marketa Kopal and H el ene Lard e who anesthetized the calves; to Marco Bosa, Nancy Larocque, Carl Bernard and Dany Hal e for their technical support; to Dr. Derek Boerboom for use of his awesome laboratory and microscope; to Dave Smith for his help with the daily care of the calves; and to Suzie Lachance and Christine Cheverier for their radiographic assistance.*

## **Abbreviations**

ESF = external skeletal fixation

TP = transfixation pincast

PS = pin-sleeve cast

## Introduction

In veterinary medicine, the great forces required to create fractures and the minimal soft tissue coverage of distal long bones in large animal species pose many challenges.[1] The rate of fracture healing depends on fracture configuration, damage to soft tissue structures including nerves and vessels, the age and size of the animal, and choice of fixation method. The success of fracture fixation depends equally on the aforementioned variables and the occurrence of complications including implant loosening, infection, implant or bone failure and cast-associated complications. For simple, transverse, non-comminuted fractures, application of a fiberglass cast as external coaptation provides adequate support, stability and early return to mobility in calves. This is an easily applied and economical solution for fracture reduction with satisfactory results.[2] This is not the case for equine patients. However, when comminution is present, a cast alone will not provide adequate support to allow fracture healing and the resulting collapse of fracture fragments may create an open fracture and subsequent infection.[3] Therefore, surgical intervention and internal or external fixation become necessary.

Longer fracture healing times are associated with mild to moderate levels of comminution.[4] Comminuted fractures require implantation of orthopedic devices to permit proper fracture healing and to anatomically align fracture fragments. Commonly used orthopedic implants include those placed at, over or through the fracture site (screws, cerclage, plates, intramedullary pins and nails); those implanted away from the fracture site (ESF with half pins and/or full pins, circular fixators); and pins implanted away from the fracture site and included in a fiberglass cast (TP). With the longer healing times of comminuted fractures, these implants must remain solidly imbedded in the surrounding bone until the fracture site is able to bear a normal physiologic load.

Normal bone healing is comprised of 4 overlapping stages.[5] The first is the inflammatory phase, which lasts on average of 3 days and encompasses the formation and resolution of the hematoma. There is a concurrent influx of granulation tissue. The second phase is that of initial bone repair lasting for 2 to 3 weeks. During this time, the periosteum

peripheral to the injury site is very active, and there is a recruitment of osteoprogenitor cells, along with intramembranous and endochondral bone formation. Three to 6 weeks after injury, the third stage, resorption, occurs where woven bone is laid down as calcified cartilage is resorbed. Secondary bone remodeling is stage 4, and this is where lamellar bone is formed in place of woven bone while the bone resumes its pre-injury physical and biomechanical properties.

Semi-rigid fixation, in comparison to rigid fixation, produces inferior callous stiffness and quality at 6 weeks in sheep with ESF.[6] Excess motion at the fracture site will impair the molecular and cellular processes necessary for bone healing.[7] This excess motion can be a result of primary inadequate fixation or secondary implant loosening. Another important factor for bone healing is adequate blood supply. If the fracture site is deprived of oxygen, it will also be deprived of inflammatory and osteoprogenitor cells.[7] Implants placed at the fracture site and the surgical approach used to place those implants can disrupt the blood supply and introduce infection. Finally, the last factor that affects healing is infection. Infection of the fracture will prolong healing times, and infection around implants destroys the bone-implant interface. Without a solid interface, the animal experiences pain, implants are loose, bone is weakened and failure of fracture fixation may occur.

Progression of fracture healing and implant loosening can be evaluated by numerous methods. Radiography is very commonly used, readily available in most practices and shows gross changes in mineralization of the fracture callous and bony changes around orthopedic implants *in vivo* and *ex vivo*. MicroCT and micro X-ray are used *ex vivo*, and bone densitometry is used *in vivo*, to give more detailed images of bony changes but the quality of the images produced can be hindered by indwelling metallic implants. Histological evaluations allow microscopic examination of fracture healing and bone-implant interfaces. Fluorescence microscopy and histomorphometry are indispensable for examining bone remodeling and osteolysis, especially at the bone-implant interface.[8-10] Biomechanically, pull-out strength and removal torque quantify the amount of integration

or loosening of the implants.[10-12] And, lastly, clinical parameters can be used to indirectly measure fracture healing and peri-implant osteolysis such as force plates, lameness grading, and pain scores.[13-15]

In large animals, the prognosis is better for young animals with long bone fractures than adults.[16] Calves are able to heal physeal fractures in an average of 4 weeks and non-physeal fractures in an average of 6 weeks; adult cattle usually require 3 to 4 months for clinical union.[17] Neonatal calves are capable of such remarkable healing rates because of a thick periosteum and rapid growth rate.[4] Equine bone healing times are slower than those reported for dogs and humans.[8, 16] Despite the rapid healing observed in young bovine patients, their bones are relatively soft and do not support plates, screws, nails and intramedullary pins.[18] Therefore, neonatal calves make an excellent model for implant loosening because of the bones' thin cortices and potentially faster lysis at the bone-implant interface.

This research project was designed to study a novel implant that was created to respond to specific needs of large animal orthopedists. Using a neonatal calf model, this project evaluated the PS system, which is optimized to decrease peri-implant strain and evenly share stress at the bone-implant interface. It was hypothesized that PS would result in less peri-implant osteolysis compared to TP. By analyzing patient comfort, lameness scores, radiographic changes over time and histomorphometric parameters, a global clinical view of peri-implant osteolysis was assessed.

# Literature Review

## Chapter I – External skeletal fixation

A variety of implants for external fixation exist to obtain apposition, anatomic alignment and stability of fracture reduction including external fixator frames, Ilizarov fixators and TP. Most of these devices are made of 316L stainless steel and may be used individually or in combination. The possibilities are limited by anatomy, fracture configuration, temperament of the animal, surgeon creativity and experience, available resources and economics.

**1.1 ESF specific to large animals.** The most important goal of ESF is to return the animal to full weight bearing with a frame that does not hinder limb use.[19] With ESF, three approaches can be used: closed (placement of implants at a site distant from the fracture site thereby limiting further trauma to the hematoma and local blood supply), open (“but do not touch”), and open with precise reduction (with or without implants). If the fracture is open, ESF allows you to achieve proper reduction while having access to infected soft tissues.

A unilateral, uniplanar external fixator, type I.A, is created with half pins and has a single connecting bar. Unilateral, biplanar external fixators, type I.B, are also created with half pins, but have 2 connecting bars. A bilateral external fixator has 2 connecting bars, but utilizes full pins, type II. Bilateral, biplanar external fixators, type III, have three connecting bars and are made with half and full pins. The type III external fixators are the strongest in resisting axial loads and torsion, where as the type I.A are the weakest.[20, 21] A study by Sullins and McIlwraith compared type II and type III ESF in foals with tibial osteotomies. Faster healing times and increased animal comfort was seen in the foals with the type II ESF. This was attributed to less soft tissue irritation and ability of pin tract discharge to drain – the half pins of the type III ESF had created abscesses and in one case extended to

cause septic arthritis.[21] A free-form external fixator can be created by using a polymer to interconnect the pins instead of sidebars.

Circular or Ilizarov fixators consist of circular frames fixed in position by threaded rods with Kirshner wires placed under tension connected to the circular frame.[19] The wires commonly used range in diameter from 1.5 mm to 2 mm.[22] These wires alone are not strong enough to withstand the loads and forces placed on them by any sizable patient. However, because the wires are tensioned, usually to 90 kg-force, and multiple wires are used at each ring with at least 4 rings, the Ilizarov fixator is able to provide a stable environment for fracture healing.[23] The rigidity of the system when tested in axial compression and in torsion was found to be proportional to the quantity of wires used.[24] Therefore using at least two wires at each ring, and ideally oriented as close to 90 degrees as possible will result in the strongest construct. While the majority of fractures can be managed with other means of fixation, the Ilizarov fixator is best used for fractures with large amounts of bone loss, when there is a high degree of comminution or for articular or periarticular fractures.[22]

Transfixation pin casting utilizes the same full pins as type II external fixators, and instead of connecting bars, the pins are incorporated into fiberglass casting material. The cast takes the place of the sidebars.[25] Most often, 2 to 3 positive profile pins are inserted proximally to the fracture and separated by 2 to 4 cm.[26] Positive profile pins are recommended because of the stronger bone-implant interface between the threads and adult equine cortical bone when compared to smooth pins. The advantage of TP is that the distance between the bone and frame/cast is minimized. Pin placement is restricted by fracture configuration and soft tissue structures. The biomechanical forces are shared between the pins and the cast, and there is no load on the fracture site, which means minimal distraction and interfragmentary movement. The possible disadvantages of this system are less access to soft tissues compared to other external fixators, pin loosening, pin



tract infection, contracted feet, tendon laxity, osteoporosis, pressure sores and ring sequestrum formation around the pin.[26, 27]

Transfixation pin casts have been used to treat comminuted, mid to distal limb fractures with success in many large animal species. In two retrospective studies on equine patients with comminuted distal limb fractures treated with TP, healing was noted in 27 of 35 patients, and 8 of 19 patients.[28, 29] In farm animals, many reports of fracture healing with TP highlight the versatility and utility of this technique. Comminuted metacarpal or radial and ulnar fractures were treated in 5 small ruminants and 1 calf with transfixation pins and fiberglass casting, with all animals regaining use of the fractured limb.[30] In 5 calves with tibial fractures, clinical and radiographic evidence of fracture healing was observed at a mean of 8 weeks with TP.[31]

**1.2. Optimization of ESF configurations.** Type II external fixators can be applied to the distal limb of large animal orthopedic patients without excessive soft tissue damage and without interfering with locomotion. When incorporated into walking bars or walking cast immediate weight bearing is possible.[32, 33] As the animal walks on its limb, the load is transferred from to bone to the pins and then the sidebars. Pin stiffness is proportional to the fourth power of the pin diameter, and pin deflection is related to the cube of the distance between the bone and sidebars.[33] The further the sidebars are from the limb, the more pin bending can occur.[34] Thus, a cast is an ideal replacement for and hybrid of the sidebars and walking bar because the distance from the limb to the cast is only the soft tissue and cast padding.

Many biomechanical tests have been completed *ex vivo* to optimize the configuration of ESF, and specifically TP. Equine metacarpi were tested to failure in torsion either as an intact bone or with a single, bicortical defect located in the mid diaphysis of 5/16 inch or 3/8 inch diameter. While torsional stiffness was unchanged by the presence of either sized defect, it was noted that increasing the size of a hole by 1/16 inch (1.58mm) created stress riser, which significantly decreased yield. The smaller, 5/16 inch

hole, had decreased post yield measurements compared to intact bone, but was still able to undergo some plastic deformation.[35] Another test, examining the torsional strength of equine radii found that a 9.5 mm bicortical defect significantly decreased the torsional strength of the bone and that there was no significant difference when additional defects were present or when the transfixation pins were loaded. Their recommendation was that in the adult equine radius, up to three 6.35 mm transfixation pins can be used, which would optimize stiffness without a significant decrease in bone strength.[36]

The size of the core pin diameter is crucial to the strength of the fixation. If the pin is too small, it will be too weak to support the weight of the animal and break; if it is too large, it will weaken the bone to a point where the bone will no longer be able to tolerate the weight of the animal.[34] The presence of a bicortical defect (i.e. pinhole) in long bones remains the major contributing factor reducing the strength of the bone. Even a defect that was 10% of the bone diameter significantly decreased the peak torque and energy absorption under torsional loading.[37] The general recommendation for choice of pin is that the shaft diameter is to not exceed 20 to 30% of the bone diameter for humans, small animals and large animals.[27, 33-35, 38] In Joyce's retrospective of comminuted phalangeal fractures in horses, failure at the pin was seen in 4 animals and three of these were at the proximal pin in the mid-diphysis (in the metacarpus or metatarsus). This was attributed to the smaller diameter of the bone and therefore relatively larger diameter of the pin relative to the bone.[25] An additional study found that the TP can be further optimized by creating divergence between the pins. The pins are still oriented medial to lateral, perpendicular to the axis of the long bone, but 2 pins placed 30 degree divergence in the frontal plane were stronger than 2 pins placed perfectly parallel to each other. The divergence allows the pins to traverse the maximal diameter of the medullary cavity, remain engaged in thick, strong cortical bone and avoid soft tissue interference.[39]

The location of the pin in the bone affects how much of the load of weight bearing is applied.[40, 41] In a study of a walking bar with transfixation pins on fresh equine

cadaver forelimbs, strain measurements were recorded above, below and in between three pins situated in diaphyseal bone of the metacarpi. When the limb was loaded axially, the strain recorded at each site decreased distally until almost no strain was detectable below the last pin.[41] A finite element analysis of another ESF in diaphyseal bone found that more stress was detected around the proximal implant than bone distally.[40] These studies suggest that the most bending of the implants and the highest amount of bone stress and strain should be observed at the proximal implant. It could be inferred that with repeated loading, more osteolysis should be seen at the proximal bone-implant interface than distally. However, both of these studies evaluated implants in diaphyseal bone which has thick cortices and has better holding power for implants than metaphyseal bone.[42] Thin cortices are present in metaphyseal bone. When axial extraction was attempted of threaded transfixation pins in metaphyseal and diaphyseal bone, no failure was observed in specimens with thick cortices.[42] Of the three bones that did fail in the study, all had metaphyseal implants. Therefore, not only does the location of one implant in relation to the others determine how much of the forces of weight bearing it will take, but implant's location relative to the bone and its cortices will also affect its behavior and biomechanics.

**1.3 Complications associated with transcortical pins.** Despite surgeons' best efforts and research to maximize the strength and stability of ESF, and more specifically TP, complications are frequently encountered. The most commonly reported complications are implant loosening, infection, implant failure, bone failure, and complications associated with cast utilization.[28, 30-34, 43] The longevity of ESF is directly related to solid bone-implant interfaces and absence of pin tract osteolysis, pin tract infection and pain to the patient.[27] Thermal necrosis during drilling and pin insertion can also lead to loose implants.[44] Clinically, to avoid encounters with the disadvantages of TP and to maximize the potential benefits of the system, it is recommended to predrill the pin holes with smaller drill bits to decrease thermal damage to surrounding bone. A 0.1mm radial preload and tapping the threads for positive profile pins increases the stability of the pins within the bone cortices and avoids the creation of microfractures.[26] Adequate padding between the

limb and the cast provides protection of bony prominences and is crucial for avoiding pressure sores.[45]

Aseptic pin loosening can occur in osteopenic bone.[46] Loose pins are at a greater risk for pin tract infection.[34] Implant loosening and infection create a vicious cycle and often occur before clinical fracture union.[28] Pin tract infection permits implant loosening by contributing to osteolysis and necrosis and can result in bony failure.[28] Clinical signs of peri-implant infection are lameness, redness, drainage, and local pain. Pin tract infection and pin tract osteolysis are not synonymous, but are often present together and contribute to the development and propagation of the other.[47] It is important to be cognoscente of the differences between a superficial infection, pin tract infection, and osteomyelitis as their influence on prognoses are not equal. Human literature describes six grades of pin loosening, which are not used in veterinary literature.[48]

**1.3.1 Implant infection.** Superficial infections usually occur as a result of soft tissue irritation by pin motion, are more commonly observed with increasing soft tissue coverage, resolve with pin removal, and can be avoided by avoiding musculo-tendinous areas.[46, 47] Although there is patient discomfort with these superficial infections, the integrity of the external fixation is usually not compromised. Pin tract infections are localized to the area immediately around the pin and do not affect the medullary cavity. The presence of an infection along the length of the pin plays an important role in implant loosening and is often reported at implant removal.[28] If the infection left untreated, catastrophic failure may result.[32, 33] Osteomyelitis is, by definition, an infection of the bone involving the medullary cavity. Osteomyelitic bone creates patient discomfort, delayed healing times, is difficult to treat and may also contribute to catastrophic failure.[28]

In an experimental study of six calves with a type II ESF made from four, centrally threaded pins and osteotomy of the right metacarpus, discharge was noted around 21 of the 24 pins, and osteolysis was apparent around 10 of the pins on radiographs.[11] In a clinical

case series of small ruminants with TP, infection was noted radiographically as osteolysis around the pins of the calf with a fractured radius and ulna.[30] Pin tract infection rate appears to be lower in TP than with other ESF, likely as a result of tissue protection by the casting material. [49]

**1.3.2 Implant loosening.** Implant loosening is also a result of normal implant loading. With each cycle of weight bearing, stress is concentrated at the bone pin interface resulting in bending of the pin.[50] This cyclic motion at the bone-pin interface creates osteolysis, which results in implant loosening.[49] Once a pin is loose, pain develops, and the contralateral limb will be overloaded.[26] This pain is a result of activated nociceptors in the periosteum.[51] In addition to decreasing the patients' comfort, implant loosening also compromises the construct stability because there is no longer a solid bone-implant interface.[16]

**1.3.2.1 Biomechanical considerations of implant loosening.** For patients with external fixators, each step and every attempt to stand up, lay down or kick not only loads the external fixator with their body weight, but also places it under axial compression, shear, bending and torsion forces[34]. This places strain on the bone-implant interface from the moment of recovery after surgery. In the presence of a fracture gap, peri-implant stress on the bone can reach high levels during weight bearing. Aro et al described fracture reduction with external fixation as “a race between the gradually increasing load carrying capacity of a healing bone and the failure of the bone-pin interface”.[12]

Pin bending is the result of uneven stress distribution between the implant and the cortical bone. This results in peak stress concentrations on the outer cortices.[50] Up to 90% of the stresses generated at the bone-implant interface are attributable directly to pin bending.[52] When a type I ESF was examined for cortical bone reactions in canine test subjects, only the cis- cortex showed radiographic and histologic evidence of pin loosening.[12] Calves with type II ESF showed osteolysis at both cortices because the full pins had connecting bars on either side of the limb therefore concentrating bone-implant

stresses at both cortices.[11] Therefore, the mode by which the pins will bend depends on how they are inserted and the resulting bending moment is what leads to the osteolysis of the outer cortex and implant loosening. Figure 1 illustrates the difference in bending between type I.A and type II external fixators (or TP).

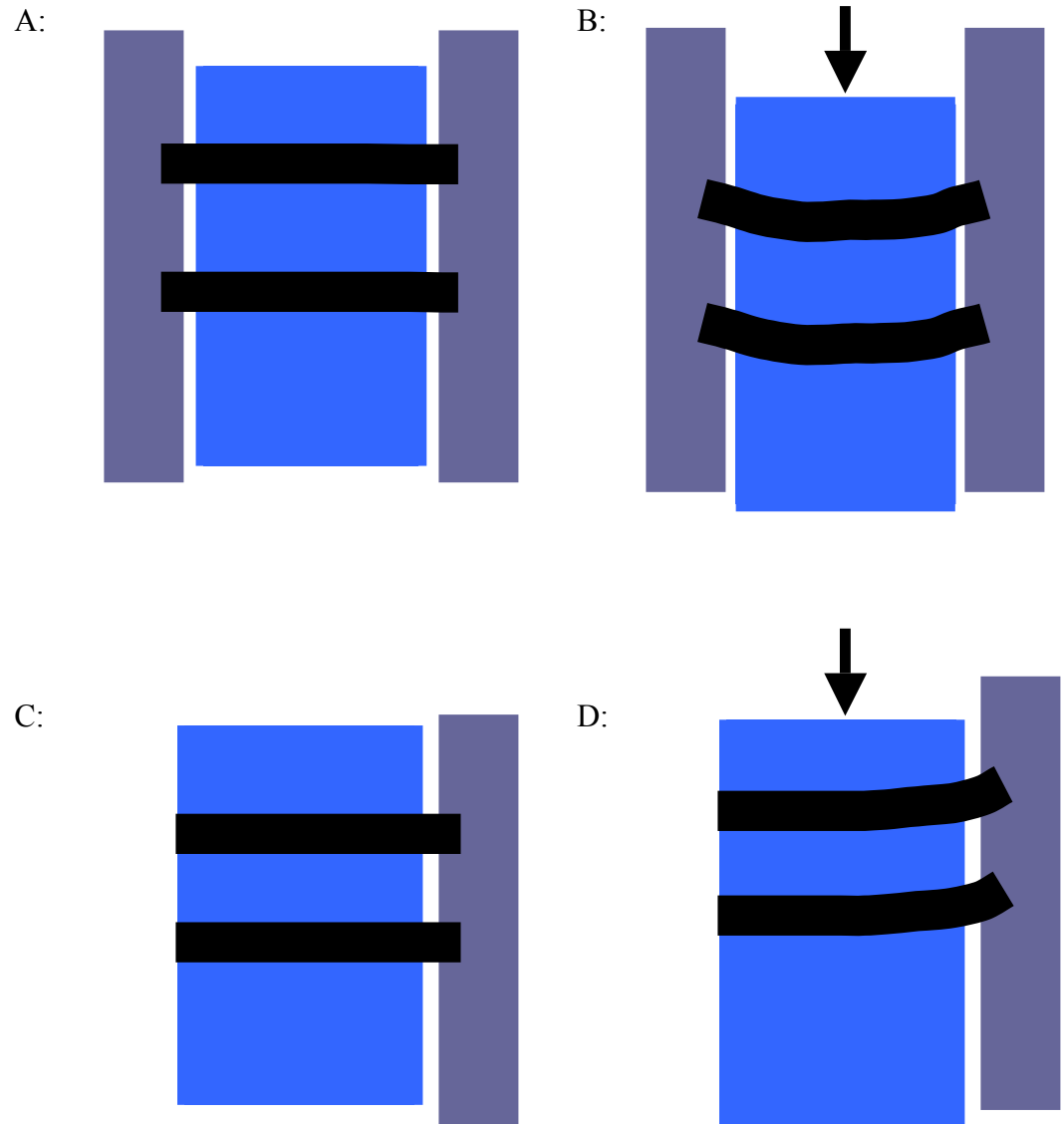


Figure 1: Diagram of pin bending with type I.A and II ESF. Schematic of a bone, in blue, implanted with two pins, in black. A and B represent a type II ESF or TP. C & D illustrate a

type I.A ESF with half pins. When the bone is loaded as shown by the arrows, pins of a type II fixator bend at both ends whereas the pins of a type I.A fixator only bend near their attachment to the sidebar, in purple. The asterisks indicate the cortices where osteolysis and subsequent pin loosening would be seen as a result of limb loading during fracture healing.

**1.3.2.2 Clinical reports of implant loosening.** Because TP mimics type II ESF using full pins that engage the lateral and medial cortices, changes are seen on the outer surfaces of both cortices. The pins are responsible for transferring the entire load of the animal from the bone, in which they are implanted, to the fiberglass cast. Pin loosening is the most common complication seen with TP and is usually associated with infection, instability, and pain.[3]

In a study evaluating two types of dynamic axial fixators in ruminants, type II ESF were placed on the metacarpi of 18 to 24 month old animals for 60 days after osteotomy.[53] Radiographs were taken every 15 days of the study, and pin tract osteolysis – defined as periosteal reaction around the pin insertion point, cortical lysis, and increased medullary density – was seen in 5 of the 6 radiographs at day 15, and thereafter was seen in every animal at subsequent time points. Pin tract drainage and sepsis was also recorded in all but one animal at days 15 and 30. These complications were more severe in the group of animals with only 2 pins on either side of the fracture (versus 3 on either side in the second group). This group also showed slower radiographic healing of osteotomy than the second group.[53]

There is a paucity of clinical data that exists specifically for TP and pin loosening. They are mostly clinical reports, case series or laboratory tests on cadavers. In the reports on comminuted distal limb fractures in equine patients managed with TP (with or without internal fixation) that have been published, radiographic evidence of pin tract osteolysis, when reported, was visible in 60 to 68% of the horses. [25, 28, 29] In total, catastrophic failure resulting in euthanasia occurred in 15 of the 76 reported cases (20%). Anderson and

Silviera reported the radiographic findings of the bone-implant interface in cattle with ESF.[54] All sizes of pins included, osteolysis was seen in 15 of 36 pin sites (42%).

**1.3.2.3 Attempts to prevent implant loosening.** In light of the serious problems pin bending and subsequent pin loosening can cause, many studies have examined possible methods to decrease the peri-implant strain by changing the size or configuration of existing materials, by coating the implants with osteoconductive materials or by adding new hardware to the implants. Even with current information and improvements, pin loosening remains an unsolved and important problem of ESF.

As discussed earlier, the stiffness of external fixation can be increased by using positive profile, centrally threaded pins where the threads engage both cortices and by increasing the diameter of pins used, but it is not recommended to exceed 20% of the bone diameter.[27] Pre-drilling holes at a low speed with smaller drill bits will decrease the thermal necrosis created, and a radial preload of 0.1mm will firmly seat the pin in the cortices.[26]. Creating 30 degrees of divergence will optimize the TP system.[39]

Coatings used on implants are used with the goal of increased osseointegration.[47, 55] Threaded implants (pins or screws) can be dipped or submerged into a solution,[10] solution precipitated,[11] or implanted into a drilled hole where the compound has been injected.[8] With the use of implant coatings, osteoinductive compounds may also be incorporated onto the coating surface.[10] In an ovine model where the screws were unicortical and non-weight bearing, bone morphogenic protein-2 did not stimulate osteogenesis and a barrier effect of polycaprolactone prevented new bone formation between the screw threads.[10] The bovine model examining calcium phosphate coating of pins in a fracture model found less discharge and more osseous integration in coated pins than non-coated pins, although a difference pin loosening was not recorded between the two groups.[11] Lastly, bone cements made from calcium, magnesium or polymethylmethacrylate were tested with non-weight bearing unicortical screws in horses.



The magnesium bone cement was the only compound that promoted adjacent osteogenesis and implant-bone bonding.[8]

Hydroxyapatite coatings in humans reduce the number of pin tract infections, loose pins and the need to change pins before fracture healing.[55] In large animals, one study has tested coated transcortical pins *in vivo*. [11] When hydroxyapatite coated versus noncoated pins were tested in 2-week-old calves using a type II ESF in an osteotomized metacarpal model, radiographic evidence of osteolysis was seen around more uncoated pins (10 of 24 pins in 4 of 6 calves) versus coated pins (1 of 24 pins). While the number of pins affected between the two groups was significantly different, the number of calves with osteolysis was not.[11] These results paralleled the presence of pin tract drainage. Significantly more direct cortical bone contact was seen histologically in the animals with the coated implants, which translates to a more solid bone-pin interface.[11]

A tapered sleeve had been added to an end-threaded pin as it exits the bone for incorporation into a walking bar or TP in attempt to better distribute the strain at the bone-pin interface.[3, 50] The logic behind the taper sleeve is that the distance between the bone and external frame is decreased to essentially zero by increasing the surface area of contact of the pin with the external cortices.[50] Figure 2 is a simplified drawing of two pins with taper sleeves seated in sidebars.

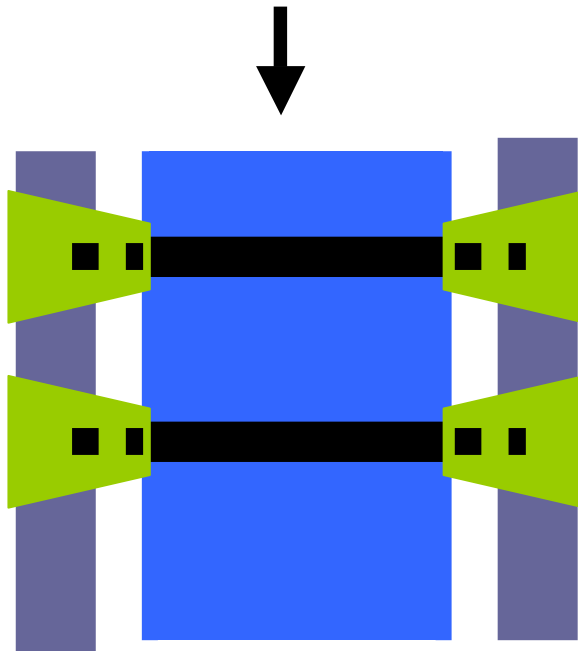


Figure 2: Diagram of taper sleeve system with type II ESF. The bone, in blue, is implanted with two transcortical pins, in black. The pins are attached to the sidebars, in purple, by tapered sleeves, in green. The increased surface area of contact between the bone and the taper sleeve eliminates a portion of pin bending. When the bone is loaded, shown by the black arrow, the pins do not bend as was illustrated in Figure 1. The dotted black lines in the taper sleeves represent the pins' attachment to the sleeves and sidebars.

In equine metacarpi, the tapered sleeve increased the stiffness of the pin compared to a normal transfixation pin and higher loads at yield with bone failure were observed.[50] When tested in osteotomized equine radii in a full limb TP, the tapered sleeves significantly increased the load to failure by 50% in axial compression. In this experiment, failure was buckling of the cast material, not bone failure.[3] There are no available clinical reports of the success and or failure of the taper sleeve incorporated into a cast to document its use. However, clinical reports of this system used with a walking bar show decreased patient

morbidity.[29] While catastrophic fracture through pin holes was noted in 5 of 7 horses with TP, none of the horses (n=5) with the taper sleeve ESF construct experienced failure.[29]

**1.3.3 Implant and bone failure.** In human and veterinary medicine, implant failure is uncommon as fixator components rarely break.[12, 21, 29, 49] However, horses may be more prone to implant failure than other large animal species because of their active nature, slow bone healing, large body size and the load and shear forces placed on the implants.[16, 29] An *ex vivo* model testing pins of various diameters in equine metacarpi in compression found that all test specimens except for one failed by bone fracture and before this occurs, marked plastic deformation is possible.[50] When tested in torsion to failure, equine metacarpi with 2 parallel pins fail with longitudinal oblique fractures where as when the pins are at 30 degrees divergence, the bones fail with comminuted fractures.[39] Neonatal bone, more specifically calf bone, does not behave in the same manner as mature bone.[31, 56, 57] This subject will be discussed specifically in Chapter 3.

**1.3.4 Cast complications.** Lastly, cast complications are a result of surface pressures under the cast. Excessive pressure underneath the cast can lead to skin ulceration.[31, 58] Because of the woven nature of fiberglass casting material, the skin surface pressures are greater under fiberglass casts compared to plaster casts.[59] In young, fast-growing animals, cast changes should be performed at 3 week intervals to allow normal limb growth and avoid pressure sores.[17] Adults are able to tolerate a single cast for a longer period of time. Adequate padding between the skin and the cast is essential.[45]

## Chapter 2 – The pin-sleeve cast

**2.1 Description of the PS system.** The development of the PS system was reported by Brianza et al. using an equine model.[51] This system was designed to have 2 implants per animal, similar to TP, but with the goal of avoiding a bone-pin interface, leaving a theoretically immobile bone-implant interface. Cyclic loading of transfixation pins concentrates strain on the outer bone cortices and results in osteolysis and subsequent pin loosening. The pin-sleeve system allows some pin movement, but the sleeve design distributes the strain differently and more evenly to the cortices.

The equine pin-sleeve system consists of a sleeve, a pin and a ring. All materials are made of 316L stainless steel. The sleeve is a 1mm thick, 45 mm long, hollow cylinder of 8mm outer diameter. Non-cutting threads of 1 mm diameter and 1 mm pitch create a total outer sleeve diameter of 8.2 mm. There are contact rims at each end of the ring to support the pin that traverses the sleeve. The rims are designed to be centered on the cortex when inserted in bone. The pin is 5 mm in diameter, 120 mm long and is secured into the ring with an axial preload. This axial preload is essential because normally, a 5 mm diameter pin is insufficient to withstand the loads of an equine patient. The ring has an outer diameter of 90 mm and inner diameter of 70 mm. Once implanted and assembled, the rings are incorporated into a fiberglass cast.[51]

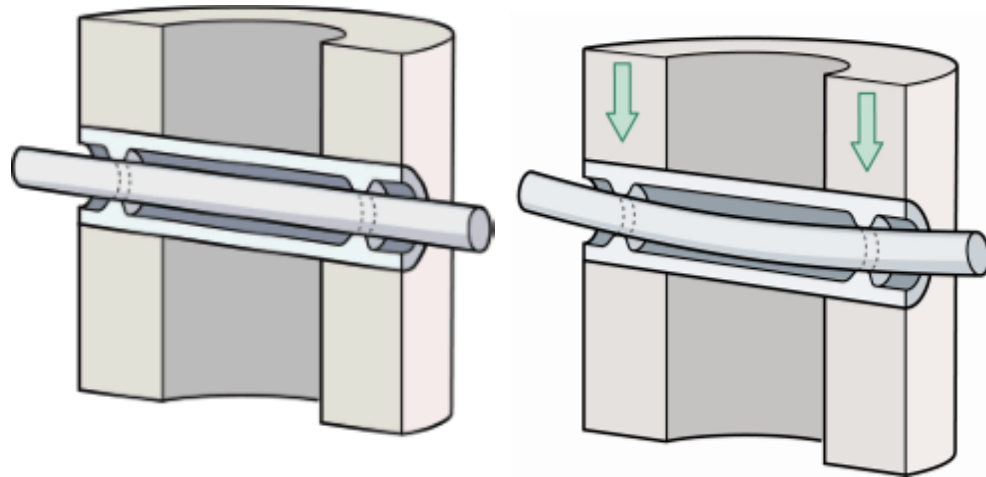


Figure 3. Diagram of pin bending in novel PS system, provided by AO Foundation, Davos, Switzerland. The sleeve and bone are shown in a cut-away fashion, and the ring is not illustrated but would be attached to either end of the pin. The contact points are visible, centered on the cortical bone at each end of the sleeve. The second image shows the load an animal would place on the bone with the arrows and the subsequent reaction of the pin within the sleeve. Note that the sleeve has not moved or bent, only the pin.

**2.2 Biomechanical properties of PS vs. TP.** The equine pin-sleeve system was tested in comparison to TP of a commonly used diameter in equine orthopedics using a bone substitute model and finite element analysis.[40, 51]

**2.2.1 Bone substitute model.** Centrally threaded, 6.3mm core diameter, 8mm outer thread diameter 316L stainless steel pins or the PS systems were implanted into the bone substitute, which was implemented with strain gauges, casted using fiberglass, and tested in axial compression. [51]

This biomechanical experiment found that the PS system is able to reduce the peri-implant strain by over 80% in comparison to TP. Varying axial preloads on the pins were also tested. A preload of 6kN was found to be the stiffest construct. This preload is essential to the pin-sleeve system because normally a 5 mm diameter implant is unable to

withstand the loads of an adult equine patient due to the moment bending area of inertia, similar to the principle of the Ilizarov fixator.[51]

This study concluded that the sleeve and the ring allow more even load transmission to the bone and the cast, respectively. The authors suggested that the sleeve could likely be left in place after cast removal in equine patients, but if the orthopedist should choose to remove it, the resulting 8.2mm defect is only 2mm larger than the outer thread diameter (8mm) of the 6.3mm core diameter transfixation pins.[51]

**2.2.2 Finite element analysis.** A finite element analysis was performed on models of equine metacarpal bones with comminuted fractures to compare TP to PS.[40] With both systems, the proximal implant and surrounding bone had more stress measured than the distal implant. This phenomenon was also recorded with the walking bar external skeletal fixation designed by Nunamaker et al.[33] Secondly, the computer-generated model showed a similar peri-implant strain distribution to the bone-substitute model on both systems, notably a significant decrease in PS axial strains compared to the transfixation pins. This stress distribution was similar whether the systems were tested in axial compression or torsion. It was also suggested that if this novel PS system could reduce pin loosening, that it may also be able to reduce the risk of fracture after implant removal.[40]

**2.3 PS scaled down for clinical trial in calves.** In anticipation of a clinical trial in a calf model and the possible use of this system in foals, a scaled-down version of the equine pin-sleeve system was created and tested *ex vivo*.[60, 61] This smaller, neonatal version consists of the same components: sleeve, pin, ring. The 6.4 mm sleeve was created to be 27 mm or 30 mm in length (depending on need), 0.8 mm in thickness with the same diameter and pitch of threads for a total outer diameter of 6.6 mm. A 4 mm diameter, 90 mm long pin is inserted through the sleeve and has contact with 2 circular support rims inside the sleeve that should be centered on each cortex once implanted. The ring into which the pin is secured with 4 mm nuts to an axial preload of 4 kN has an outer diameter of 70 mm and inner diameter of 50 mm. A 4 kN preload was determined from the computer models of the

adult system. The ring is constructed from 2 half-rings that are bolted together. Each half-ring has 2 possible placements for the pin: central and eccentric. This allows the ring to be centered around the limb by having 4 possibilities for securing the pin, Figure 4.

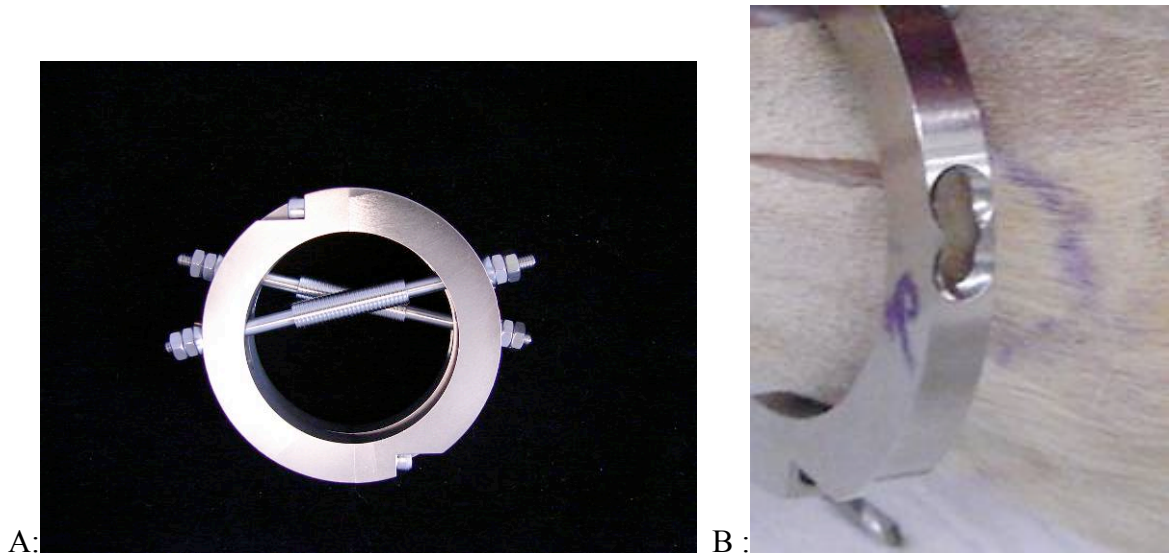


Figure 4. Photographs of the PS system. A: The possibilities for pin orientation in the ring are shown. B: Side view of the ring on a cadaver limb showing a close-up of the site of pin attachment. Photographs courtesy AO Foundation, Davos, Switzerland.

This neonatal PS system was tested in comparison to centrally threaded transfixation pins of 4.8 mm core diameter and 6.4 mm outer thread diameter. Two tests were performed: strain measurement in metacarpal bones[61] when loaded axially and torque to failure post implant removal to test the defect left by each implant system in metatarsal bones[60]. All bones were obtained from 4 to 6 week old dairy calves. Two implants per bone were placed at 25° divergence. The recommended 30° divergence from the equine literature could not be respected due to the less cylindrical nature of the calf bones.

For the metacarpal bones, strain gauges were attached proximally to the proximal implant before cast application. The specimens were loaded in the elastic range, and then

tested until failure. In both the TP and PS cast groups, failure occurred by delamination of the fiberglass casts and not by bone or implant failure. The strain recorded was over three times greater for TP than for PS. These results parallel the decrease in strain measured on the bone-substitute tests results in the adult, equine indicating that the scaled-down model is appropriate for use in smaller diameter bones and on smaller, lighter animals.[61]

The metatarsal bones were implanted with their respective system and then tested to failure by external rotation. Measurements of bone mass, length, width, and cross-sectional diameter at each implant were recorded. The resulting distal PS defect was significantly larger than the TP with respect to the bones' cross-sectional diameter. All bones failed by spiral fracture through at least one implant hole. Both systems showed similar angular displacement, torsional stiffness, torque at failure and failure angle. Both systems created comparable notch effects in cadaver calf metatarsal bones.[60] The measurements of systems tested, both adult (equine) and neonatal (calf), and the test results are summarized in Table I.

	ADULT		NEONATE	
	TP	PS	TP	PS
<b>Core diameter (mm)</b>	6.3	8.0	4.8	6.4
<b>Outer thread diameter (mm)</b>	8.0	8.2	6.4	6.6
<b>Axial loading strain (<math>\mu</math>strain)</b>	2841	463	1737	501
<b>Torque failure angle (Nm)</b>			14.76	15.45

Table I: Data from *in vitro* and *ex vivo* PS vs. TP testing. Implant dimensions and recorded measurements during biomechanical testing of the traditional TP and the novel PS in both an adult and a neonatal model.

In light of the performance of the PS system in the laboratory, a clinical trial was necessary to tests the biological behavior of bone with the two systems. A calf model was chosen because of its potential to more quickly demonstrate implant loosening.



## Chapter 3 – Calves as a model for implant loosening

Two general types of bone exist: woven and lamellar. Woven bone consists of randomly arranged collagen fibers in an osteoid matrix, Figure 5. Woven bone is considered an immature form of bone that is made during fetal development and fracture healing. Lamellar bone, Figure 6, is composed of regular, parallel bands of Type I collagen arranged in sheets with calcium hydroxyapatite interspersed, which gives lamellar bone its strength and rigidity. Virtually all healthy adult bone is lamellar; cancellous and cortical bone are both types of lamellar bone.[62] Dense, compact, cortical bone is found in the diaphysis of adult long bones and is harder, stronger and stiffer than cancellous bone, Figure 7.

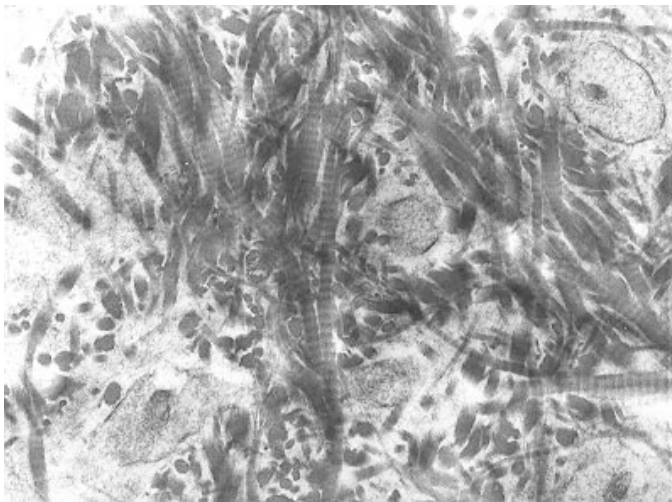


Figure 5. Woven bone. (Courtesy Robert M. Hunt) Disorganized arrays of collagen fibrils in a osteoid matrix.

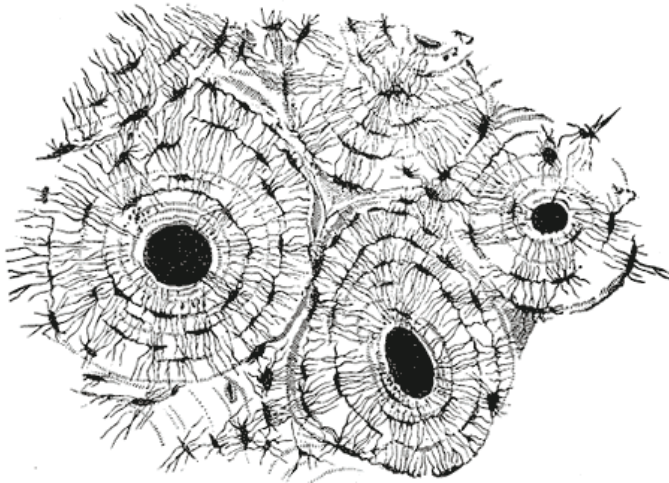


Figure 6. Cortical bone. Cross section showing the structure and organization of osteons and centrally located Haversian canals. (20th U.S. edition of Gray's Anatomy of the Human Body, originally published in 1918).

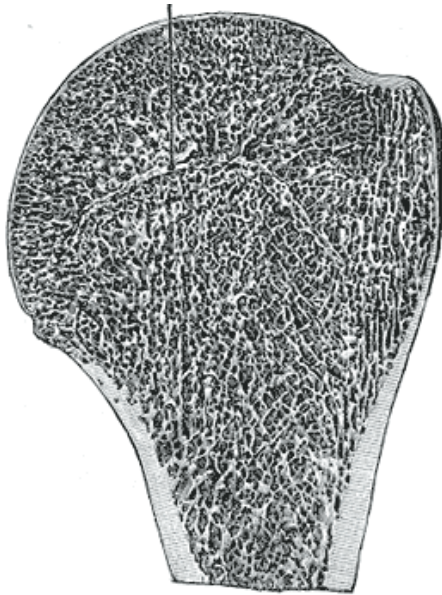


Figure 7. Cancellous bone. Longitudinal cut from the head of a femur; the cancellous bone is visible proximally. Distally, cortical bone becomes visible with cancellous bone in the medullary cavity. (20th U.S. edition of Gray's Anatomy of the Human Body, originally published in 1918. The vertical line is pointing to the physeal scar).

**3.1 Physical properties of neonatal calf bone.** During maturation, the woven bone of the neonatal skeleton is remodeled to lamellar bone. This means that at birth, a calf's skeleton is mostly composed of woven bone.[62] Long bones in calves have relatively thin cortices, which provide for minimal bone-implant contact. The woven nature of the bone provides an environment where the thin cortices do not allow adequate holding power of implants and thus permit premature implant loosening and motion at the fracture site.[18, 63] The bone that is present has such a low density that orthopedic repair of neonatal bovine fractures is very challenging.[64]

When neonatal calf bone was studied microstructurally, it was found to have small apatite mineral deposits in the collagen fibrils.[57] This apatite mineral has important biological and biomechanical functions. Its deposition within the collagen fibrils determines the structure-function relationships of the bone, which, in turn, depend on the amount of mineral deposited. In adult bone, almost 98% of the mineral depositions are small and form a plate-like arrangement. In neonatal calf bone, the mineralite is shorter and thicker than what is found in mature bovine bone.[57] Biomechanically, this means that neonatal bone is weaker and less dense than adult bone. Also, it is able to undergo more plastic deformation before failure.

**3.2 Measures of bone strength in neonatal calves.** The tensile strength of bovine bones were studied in a laboratory setting by Martin and Ishida to determine the importance of collagen fiber orientation, porosity, density and mineralization.[65] Collagen fiber orientation was found to be 'the single best predictor' of strength. Overall, mineralization of the bone matrix is a poor predictor of bone strength. The other two variables studied, porosity and density are intermediate determinants of bone strength.[65] Porosity was measured by the presence of Volkmann's and Haversian canals, and density was measured as the nanostructural compactness of collagen and mineral. Therefore, woven bone with its randomly arranged collagen fibers is inferior in strength to lamellar bone with regularly arranged fibrils of collagen. Secondly, Peterlik et al describe the toughness of bone as being determined by its composition (collagen and mineral) and its energy dissipation capacity. It

is the orientation of the collagen fibers that can predict a bone's ability to dissipate energy without fracturing or predict the orientation of the microcrack.[66] When there is a random orientation to collagen fibers, i.e. woven bone, longitudinal microcracks will not occur and therefore no bone failure, but local destruction or osteolysis will occur. Thus, ultrastructurally, calves are an excellent model for implant loosening.

Neonatal calf femurs were used to compare various methods of femoral fixation with minimal success.[18] The type I.A ESF did not immobilize the fractures because of the thin cortices present in the 35 to 45 kg calves. The plated femurs had fracture callous present at the time of euthanasia, but every plate was loose and allowed an unacceptable amount of motion at the fracture site because the cortex was too thin to allow the screws to be adequately seated.[18] Another study examined the holding power of various screws in neonatal bovine femurs.[63] Bliklager et al. found that in all tests, the screws pulled out of the bone without damage to the screw or its threads. In most cases, the screw was retrieved with a piece of fractured cortex around the screw threads. For the screws tested in metaphyseal bone, the trans cortex stripped and was left in between the screw threads.[63] These two studies demonstrate that the metallic implants used in orthopedics are much stronger than the neonatal calf bone into which they were implanted. These *in vivo* and *ex vivo* studies show how the microscopically weak structure of neonatal calf bone translate to suboptimal conditions for internal and external fixation.

**3.3 Neonatal calves as a model for implant loosening.** Implant loosening seems to be a sometimes-unavoidable consequence of fracture fixation. It stands to reason that implant loosening occurs faster in 'softer' or woven bone than in lamellar bone. Therefore, if one wanted to study the effects of implant loosening, calves provide an appropriate model. Changes seen around orthopedic implants in neonatal calves should occur to an exaggerated degree and in a shorter period of time than other species and older bovines.

## **Article**

**TITLE:** Evaluation of a novel transcortical pin-sleeve system in a calf model

### **AUTHORS**

Susan R. Vogel<sup>1</sup>

André Desrochers<sup>1</sup>

Stefano Brianza<sup>2</sup>

Christiane Girard<sup>3</sup>

Sylvain Nichols<sup>1</sup>

Christian Bolliger<sup>1</sup>

Kate Alexander<sup>1</sup>

Ludovic Bouré<sup>2</sup>

From Université de Montréal, CP 5000, St-Hyacinthe QC Canada

<sup>1</sup>Department of Clinical Sciences; <sup>3</sup>Department of Pathology and Microbiology

<sup>2</sup>AO Research Institute, Clavadelerstrasse 8, 7270 Davos Platz, Switzerland

A portion of this project was underwritten by the AO Research Institute, Davos Platz, Switzerland. Funding provided by Pfizer research funds and fonds du centenaire from the Université de Montréal.

## ABSTRACT

**Objective:** To evaluate a novel pin-sleeve and ring cast system (PS), which is optimized to decrease peri-implant strain and evenly share stress at the bone-implant interface, in a neonatal calf model and compare its performance to transfixation pincasts (TP).

**Study design:** Clinical trial

**Animals:** Ten, 3-week-old, healthy dairy calves

**Methods:** Calves were implanted with either TP (n=5) or PS (n=5) in the right metacarpi, 2 implants per calf. Calves were scored daily for lameness and were euthanized at day 28. Collected data included radiographs at surgery and euthanasia and histomorphometric measures of bone-implant contact on non-decalcified specimens with the implants *in situ*. Data was analyzed using Cochran-Mantel-Haenszel test; a P-value <.05 was considered significant.

**Results:** The cortical thickness was larger for distal implants than proximal implants for both groups at surgery (P=.03), but were similar between groups (P>.31). TP calves developed lameness sooner (median lameness score 3/4), at day 21, than PS calves (median lameness score 1/4) (P=.04). Histologically, there was more direct cortical bone-implant contact for PS distal implants than TP distal implants (P=.04).

**Conclusions:** The metaphyseal-diaphyseal junction where the proximal implants were situated is unsuitable bone for either system; each had minimal bone-implant contact and extensive osteolysis. The PS system did not cause significant osteolysis when instrumented in diaphyseal bone and should be considered a suitable alternative to TP for comminuted distal limb fractures.

## INTRODUCTION

Transfixation pincasts (TP) are used in large animal orthopedics for external fixation of comminuted distal limb fractures with inconsistent success. Peri-implant osteolysis, pin loosening, and pin tract infection are commonly encountered problems with TP that, while non-catastrophic in themselves, can lead to delayed healing or failure.<sup>1-6</sup> These complications are, for the most part, centered on the bone-implant interface and arise from continued, cyclic micromotion of the pin caused by weight bearing and ambulation.<sup>7</sup> The longevity of external fixation is directly related to solid bone-implant interfaces and absence of pin tract osteolysis, pin tract infection and pain to the patient.<sup>8</sup> Stress concentrated on the proximo-external and disto-internal cortices of the bone-pin interface causes pin bending, osteolysis, pain for the patient and often necessitates removal before adequate functional fracture healing.<sup>7,9</sup> In addition to decreasing the patients' comfort, implant loosening also compromises the construct stability because there is no longer a solid bone-implant interface.<sup>10</sup>

Recently, a pin-sleeve (PS) system was developed by Brianza et al. using an adult, equine model.<sup>9,11</sup> This system was designed to avoid a bone-pin interface, leaving a theoretically immobile bone-implant interface. The sleeve with non-cutting threads has contact rims inside each end to support the pin that traverses the sleeve; the pin is connected to a ring that encircles the limb and is incorporated into a cast. An axial preload is essential to the PS pin because without it, its diameter is insufficient to withstand the loads of an equine patient.<sup>11</sup> Two implants per animal are used similar to TP. The PS system allows some pin movement, but the sleeve design distributes the strain more evenly to the cortex. The load is transmitted from the pin to the sleeve at two contacts rims only which are centered on each cortex.<sup>9,11</sup>

When equine PS system was tested in comparison to TP using a bone substitute model, the peri-implant bone strain decreased by over 80% in PS specimens.<sup>11</sup> The authors suggested that the sleeve could likely be left in place after cast removal in equine patients, but if the orthopedist should choose to remove it, the resulting 8.2mm defect is

only 2mm larger than the outer thread diameter (8mm) of the 6.3mm core diameter transfixation pins.

In anticipation of a clinical trial in a calf model and the possible use of this system in foals, a scaled-down version of the equine PS system was created and tested *ex vivo*.<sup>12,13</sup> This neonatal PS system was tested in comparison to centrally threaded TP. Two tests were performed: bone strain measurement in axially loaded metacarpi and torque to failure post implant removal to test the bone defect left by each implant in metatarsal bones. The strain recorded was over three times greater for TP than for PS, paralleling the bone-substitute tests results in the adult, equine model.<sup>13</sup> In the notch effect study, the metatarsal bones failed by spiral fracture through at least one implant hole, and both systems showed similar angular displacement, torsional stiffness, torque at failure and failure angle.<sup>12</sup>

Neonatal bone, more specifically calf bone is relatively soft, has thin cortices, and changes around orthopedic implants occur to an exaggerated degree and in a shorter period of time than in other species and older bovines.<sup>4,14,15</sup> The purpose of this study is to compare clinically, radiographically and histologically this novel PS system to the commonly used TP in a calf model. It was hypothesized that PS would result in less peri-implant osteolysis compared to TP. The PS system is expected decrease the morbidity associated with TP.



## MATERIALS AND METHODS

The lab animal care and use committee of the Université de Montréal approved this project.

This project evaluated a novel orthopedic implant in a neonatal calf model that is composed of a hollow sleeve (6.4 mm diameter, 0.8 mm thick, 1mm diameter threads with 1 mm pitch, total outer diameter 6.6 mm) implanted in the bone with a pin (4 mm diameter, 90 mm length) that traverses the sleeve and is secured into a ring (outer diameter 70 mm, inner diameter 50 mm), which is then incorporated into a cast, Figure 8.



Figure 8. Photograph of the neonatal PS system. The 4 mm pin traverses the 6.4 mm diameter sleeve and is secured to the ring using 4 mm nuts. The ring has an outer diameter of 70 mm and an inner diameter of 50 mm. At the top of the photo, the sleeve is shown mounted onto the insertion instrument.

A total of 10, 2-week-old, intact, male calves were used for this study: 8 Holstein and 2 Jersey calves. During the entire study period, the calves were examined daily:

temperature, pulse, respiratory rate and pain scores were recorded along with any other physical exam findings. The pain scoring system was adapted from a previously published criteria taking into account elevations in heart and respiratory rate, lameness and appetite, Table II.<sup>16</sup> For scores greater than 7, butorphanol (0.05mg/kg SQ q 12 hr) was given until a sustained decrease of pain score. If an animal was found to be non-responsive to butorphanol, NSAID administration (Ketoprofen 3 mg/kg IV) and a cast change, it was euthanized before the study end-date for humane reasons.

<b>Lameness</b>		<b>Appetite (amount consumed)</b>	
None	0	90 – 100%	0
Grade 1 (slightly asymmetric gait)	1	89 – 90%	1
Grade 2 (animal clearly favors limb)	2	70 – 80%	2
Grade 3 (severely lame)	3	60 – 70%	3
Grade 4 (non-weight bearing)	4	< 60%	4
<b>Limb manipulation</b>		<b>Heart &amp;/or Respiratory Rate (% increase)</b>	
No sign of pain	0	0 – 10%	0
Moves head towards manipulated limb	1	10 – 20%	1
Pulls leg away	2	20 – 30%	2
Moves head and pulls leg away	3	30 – 40%	3
Painful above cast	4	> 40%	4

Table II: Pain score chart. This table was used daily to score the overall pain of each calf. Score totals were ranked as follows: 0-3 = no pain, 4-7 = mild pain, 8-11 = moderate pain; 12+ = severe pain. Lameness scores were adapted from those described by Bicalho et al, Journal of Dairy Science 2007.<sup>37</sup>

On arrival, blood was drawn from the jugular vein for standard complete blood count, biochemical profile and BVD testing. Fecal samples were submitted for salmonella culture. The calves arrived one week before surgery to allow for acclimatization and were randomly assigned to either the TP (n=5) or the PS (n=5) group. They were housed in pairs in 2.5 m<sup>2</sup> stalls at the teaching hospital. The calves were fed

10 – 15% of their body weight daily in milk replacer (up to 6 L per day) and had free access to grass hay, calf grain and fresh water.

Jugular catheters were placed before surgery and food was withheld for at least 8 hrs. Sedation was induced with butorphanol (0.01 mg/kg IV) and xylazine (0.15 mg/kg IV). With the calf in dorsal recumbency the shoulder and axillary region of the right front limb was aseptically prepared, and the calf was naso-tracheally intubated. A brachial plexus block was performed with 2% lidocaine (0.5 ml/kg) under nerve stimulator<sup>a</sup> guidance as described by Estebe et al.<sup>17</sup> The right front limb was then prepared for surgery. During surgery the heart rate, indirect blood pressure and pulse oximetry were monitored and oxygen was administered via the naso-tracheal tube. One dose of ceftiofur (2mg/kg IV) was administered before surgery and twice daily for three days post-operatively. One dose of ketoprofen (3mg/kg IV) was administered before surgery and repeated 24 hrs later. For each surgery day, one TP and one PS calf underwent the procedure.

Sterile surgical technique was strictly observed for both groups of animals. Fluoroscopic images were used to determine implant placement by placing 20G, 3.5cm hypodermic needles along the metacarpus. The skin was then incised at the appropriate site. The proximal implant was placed in the most proximal part of maximal thickness of cortical bone (at the metaphyseal-diaphyseal junction) and the second implant was positioned 3.5 cm distally. The proximal implant was angled dorso-lateral to palmo-medial and the distal implant was angled palmo-lateral to dorso-medial creating approximately 20 degrees of divergence between the pins while still maintaining position in the lateral and medial aspects of the cortices. An aiming device with specially manufactured sleeves for the drill bits was used to ensure accuracy during the incremental drilling. Sterile saline solution was used to irrigate during all drilling. For TP, 4.8mm centrally threaded, positive profile pins<sup>b</sup> were hand inserted after incremental drilling (3.2 mm, 4.0 mm, 4.7 mm) and hand tapping. The 6.4mm PS sleeves were hand inserted after incremental drilling (3.2 mm, 4.0 mm, 4.7 mm, 5.5 mm, 6.0 mm and 6.4 mm), no tap was used. The drilled bone was flushed before implant insertion, and the sleeves were also flushed before pin insertion. Immediate post-operative dorso-palmar,

latero-medial and slightly obliqued (2 views, one with each implant parallel to the cassette) radiographs were taken before cast application. Each 4 mm pin was inserted in the sleeve and tightened to 4 Nm in its circular ring with a torque-limiting wrench<sup>c</sup>. Nonpermanent thread locker<sup>d</sup> was applied to the threads of each pin and a second nut was tightened by hand. The limbs were padded with one layer of Delta-Dry<sup>e</sup> and one layer of yellow foam cast padding<sup>f</sup>. Felt padding was placed under the accessory claws, between the claws before the Delta-Dry and yellow foam and at the top of the cast after their application. For PS calves, thin strips were also placed under the rings (over the cast padding). A low limb cast including the foot was then applied using 4 rolls of 3-inch fiberglass cast material<sup>g</sup> for each animal. For the PS calves, one roll of one-inch material was used between the rings.

At seven days after surgery, each calf received 8 mg/kg of 8 mg/ml sterile-filtered calcein green<sup>h</sup> solution subcutaneously. At 21 days post-surgery, the calves received 25 mg/kg of 25 mg/ml sterile-filtered alizarin complexone<sup>i</sup> solution IV at a rate of 4 ml/kg/hr.

Calves were humanely euthanized with a barbiturate overdose 28 days after surgery. The limbs were immediately harvested for analysis. The casts (and PS rings) were removed and the limbs inspected for pin tract infection, implant loosening and skin healing at incision sites. To remove TP casts, the cast was cut length-wise along the medial and lateral aspects. Then a diamond was cut around each pin freeing the casting material over the pin from the rest of the cast. The cast was split open and removed, and then the material over the pins was removed while care was taken not to twist or pull the pins. For the PS casts, first, a circular cut was made immediately adjacent to the distal aspect of the proximal ring. Then diagonal cut was made through the casting material between the 2 rings before the circular cuts were made both proximally and distally on the distal ring. Then medial and lateral sides of the cast were cut from the distal ring to the foot. The cast was split and removed and the rings were disassembled and the pins removed leaving the sleeves in the bone.

The same radiographic views taken post-operatively were repeated. The soft tissues were then removed, the metacarpus disarticulated from the carpo-metacarpal and metacarpo-phalangeal joints and the bone transected at the distal diaphysis. The bones were placed in 10% buffered formalin for 48 – 72 hours and then transferred to 70% ethanol and sent to the histopathology lab for preparation as described previously.<sup>18</sup>

Radiographs were evaluated for evidence of changes in cortical thickness over time, cortical fracture and changes in radio-opacity at the bone-implant interface. Each cortex of each implant (4 per implant) was measured (Figure 9.a). Measurements were made using computed radiography software<sup>1</sup>. All measurements were corrected for magnification using the pin or sleeve shaft.

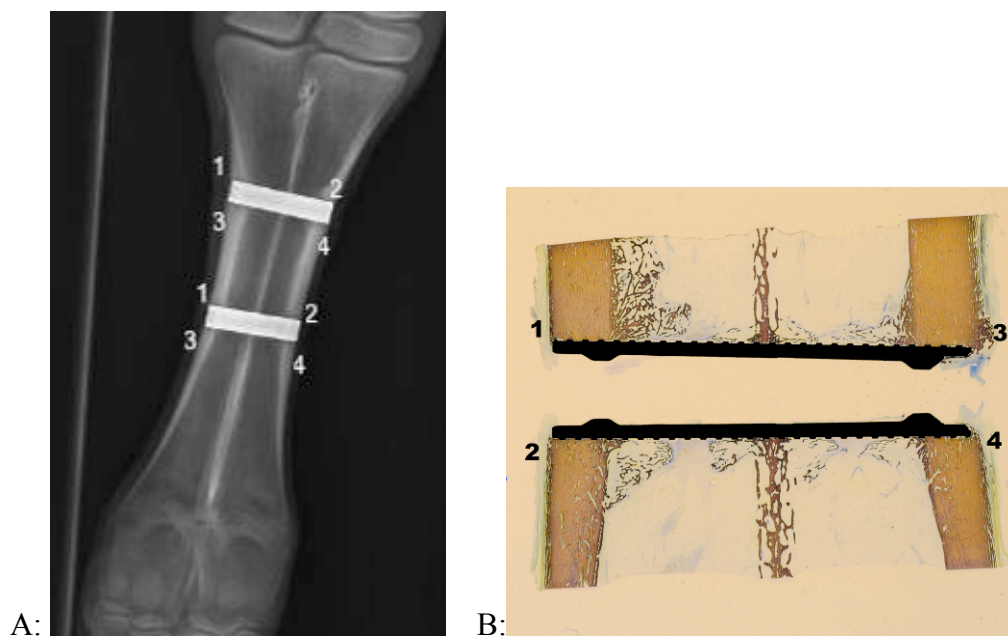


Figure 9. Labeled cortices for data collection. A: Dorso-plantar view of a PS calf at day 28. The proximal and distal cortices on the medial and lateral aspects of proximal and distal implants were labeled and measured. B: A photograph of a non-decalcified bone with distal PS implant (from the same animal as the radiograph) labeled for measurements. The length of the implant is 27 mm. For histological measurements, the same numbering scheme applied. Some bone ingrowth at the extremities of zones 3 and 4 of the sleeve can be seen.

Both implants from each calf were harvested for analysis with the surrounding bone. One slide per implant with both the medial and lateral cortices was prepared, Figure 9.b. Histopathology slides of non-decalcified bone centered on bone-implant interface were prepared along the length of the implant perpendicular to the long axis of the bone as previously described<sup>2</sup> and stained with stevenol blue. All slides were examined and scored by the same evaluator (CG). A bone-implant interface score was adapted from Jansen et al.<sup>19</sup> A score of 0 was assigned for direct cortical bone contact; 1 for irregular or remodeling bone contact; 2 for intermittent fibrous tissue & bone; 3 for fibrous tissue only contact; and 4 for inflammation around implant. An osteoclast count was performed on 5 consecutive high-powered fields for each cortex as well. Slides were evaluated using fluorescent microscopy<sup>k</sup> and peri-implant new bone growth was labeled as present or absent for each fluorochrome.

The Cochran-Mantel-Haenszel test was used to analyze body weight and weight gain over time, to analyze the pain and lameness scores between groups at given time points, and the histomorphometric scores within each group (between implants) and between groups for each implant. To determine if any difference existed between groups regarding cortical thickness, a repeated measures linear model was employed. A Fisher exact test was used to compare the number of infected implants and animals with affected implants. A *P* value < 0.05 was considered significant. Cortices 1 and 3, the proximal cortices, for each implant were grouped together as were 2 and 4, the distal cortices; proximal and distal implants were treated separately.

## RESULTS

Hematologic and biochemical results upon arrival were within normal limits. The calves did not show signs of systemic disease during hospitalization aside from mild diarrhea during the week of acclimatization. No calves tested positive for BVD or salmonella. The mean weight on arrival was  $42.6 \pm 7.7$  kg for TP calves and  $41.5 \pm 4.8$  kg for PS calves; the weight at euthanasia was  $60.8 \pm 4.2$  kg and  $64.6 \pm 6.9$  kg, respectively. There was no significant difference between the groups,  $P > 0.36$ .

All TP and PS systems were implanted without complication. It was necessary to avoid all entrapment of soft tissue when hand tapping TP bones and hand inserting PS sleeves or else insertion of the instrument was nearly impossible. The brachial plexus block provided appropriate anesthesia for these orthopedic procedures. Aside from one calf that had a transient, non-painful swelling cranial to the scapulo-humeral joint of the operated limb, no adverse effects of the brachial plexus block were appreciated. Mean surgical time was 42 minutes  $\pm 12.5$ .

Pain scores were equal to lameness scores therefore, only the lameness values are reported. TP calves developed lameness (median score 3/4) sooner ( $P = .04$ , at day 21), than PS calves (median score 1/4). At the end of the study, day 28, no significant difference existed between groups ( $P = 0.09$ ), although there was a trend of TP calves having higher scores (median score 3/4) than PS calves (median score 2/4). No bone or implant failure was observed during the study, and no pins appeared to have bent based on radiographs and gross examination after cast removal.

The measurements and scores for the proximal and distal implants of both systems are reported in Table III. For both groups, the distal implants were situated in cortical bone that had a significantly greater cortical thickness than the proximal implants. Radiographically, lysis was appreciated in 10 of 10 TP implants ( $n = 5$  calves) and 3 of 10 PS implants ( $n = 3$  calves). While the difference between the number of affected implants between TP and PS calves was statistically significant ( $P = 0.003$ ),

there was no significant difference when comparing the number of animals affected ( $P = 0.44$ ). All PS implants with radiographic evidence of osteolysis were proximal implants.

Group	Implant	Interface site	Cortex at surgery	Cortex at euthanasia	Osteoclast Index	Interface score
Transfixation Pin Cast	Proximal	1, 3	3.1 ±0.2	3.2 ±0.6	0	2
		2, 4	3.5 ±0.4	3.4 ±0.6	0	2
	Distal	1, 3	3.8 ±0.4	4.0 ±0.8	0	2
		2, 4	3.6 ±0.3	3.9 ±0.8	0	2
Pin-sleeve Cast	Proximal	1, 3	3.3 ±0.5	3.3 ±0.8	0	1.5
		2, 4	3.9 ±0.6	3.9 ±0.9	0	2
	Distal	1, 3	3.5 ±1.3	4.2 ±1.6	0	0
		2, 4	3.6 ±0.5	4.2 ±0.6	0	0

Table III: Radiographic and histomorphometric data. The cortical thicknesses are mean in mm ±SD. The osteoclast and bone-implant interface values are the medians. Interface site 2,4 for the proximal implant of both groups was significantly greater than interface site 1,3. Both interface sites combined for each implant, the distal TP and distal PS implants had significantly greater cortical thickness than their respective proximal implants. There was no significant difference between groups or implants for the osteoclast index. There was a significant difference between the bone-implant interface score of the distal PS implant and all other implants.

At the time of cast removal, small circles of discoloration were noted the dorsal aspect of the medial and lateral metacarpo-phalangeal and proximal interphalangeal joints. There was no ulceration or bruising, only slightly darker areas of skin that were not present at surgery. Skin healing around the TP and PS implants was excellent (Figure 10). The incision that had been made for TP implantation had healed and conformed to the pin. In PS calves, the skin had healed to the diameter of the pin and completely covered the edge of the sleeve that had been visible in surgery. No drainage was noted from the pin tracts or the sleeves.



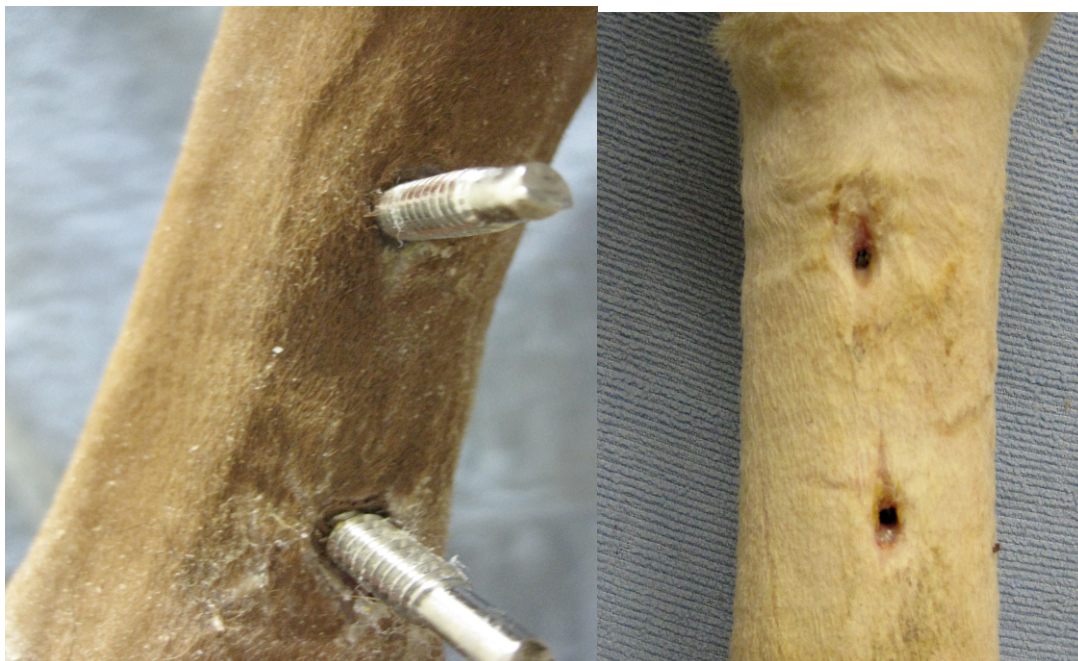

Figure 10. Photographs of skin healing. Taken immediately euthanasia of a pincast calf (left) and a pin-sleeve cast calf (right) of the pin-skin interface. The pins have been removed from the sleeves. No discharge is visible from either system.

At cast removal, all proximal TP pins were considered loose because it was possible to easily turn them with just a thumb and forefinger. Four of them were loose to a point where they were almost freely moveable in proximal-distal, dorsal-palmar and lateral to medial directions. For three of the 5 distal implants it was also possible to turn the pin by hand, but they did not wiggle in the bone as the proximal TP pins did. Because the PS sleeves did not extend past the bone cortices, it was not possible to subjectively evaluate loosening and make comparisons between the groups.

Significant differences were found between the distal implants of the two systems for the interface index ( $P < .009$ ); significantly more direct bone-implant contact was present along the distal implant of PS than TP, Figures 11 and 12. During preparation of the non-decalcified specimens, some TP implants fell out of the bone as the samples were cut. This did not damage the surface in contact with the pin, but some slides did not contain the implant, Figure 11.b, and therefore the measurements were taken following the outline of the implant. The interface index for the proximal implants and the

osteoclast index for either implant in either group showed no significant differences ( $P>.3$ ), Table III. An important difference was found between the proximal and distal implant of PS calves Figure 12, ( $P=.04$ ): there was more direct bone contact along the distal PS implant than proximal, where the same difference did not exist for the TP calves ( $P>.21$ ) indicating similarly extensive osteolysis at both TP implants, Figure 11.

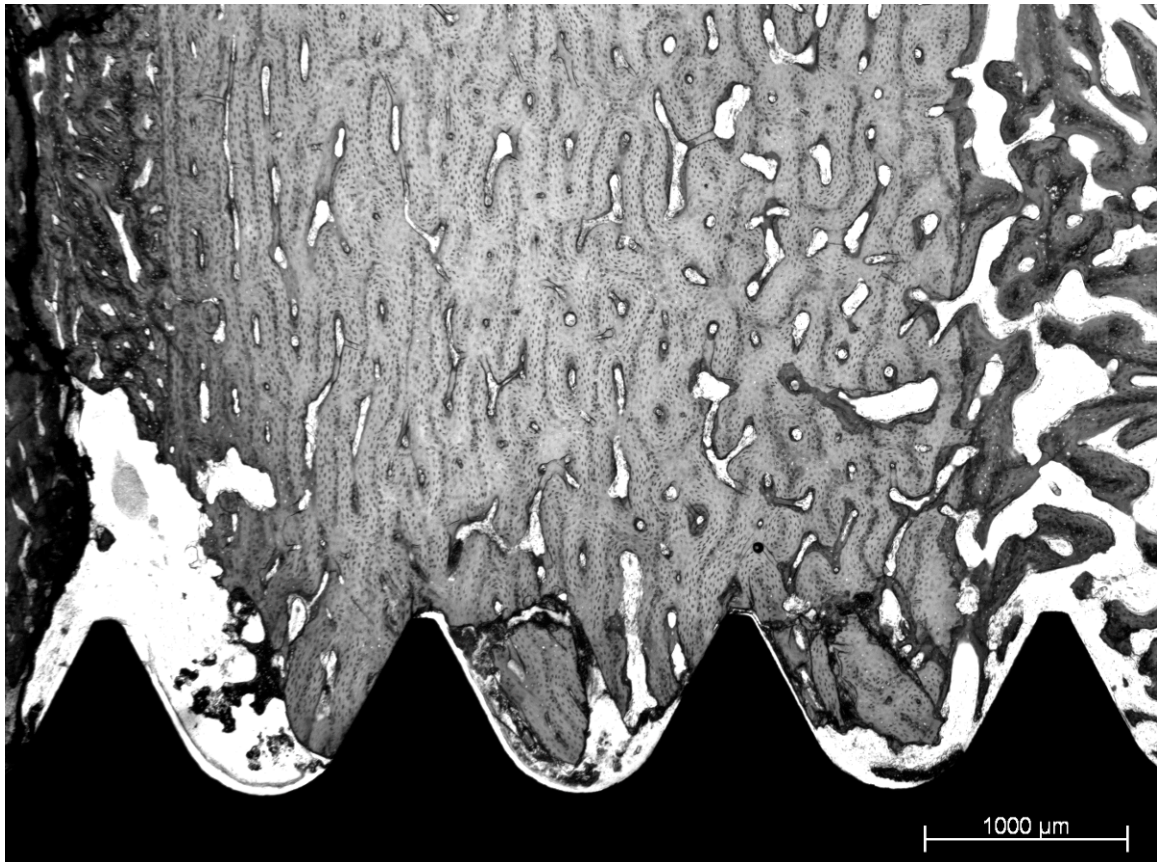


Figure 11.a. Histology of proximal TP implant. Photomicrograph of a non-decalcified specimen, stevenol blue stain. Interface index score of 2 (intermittent contact of fibrous tissue and bone).

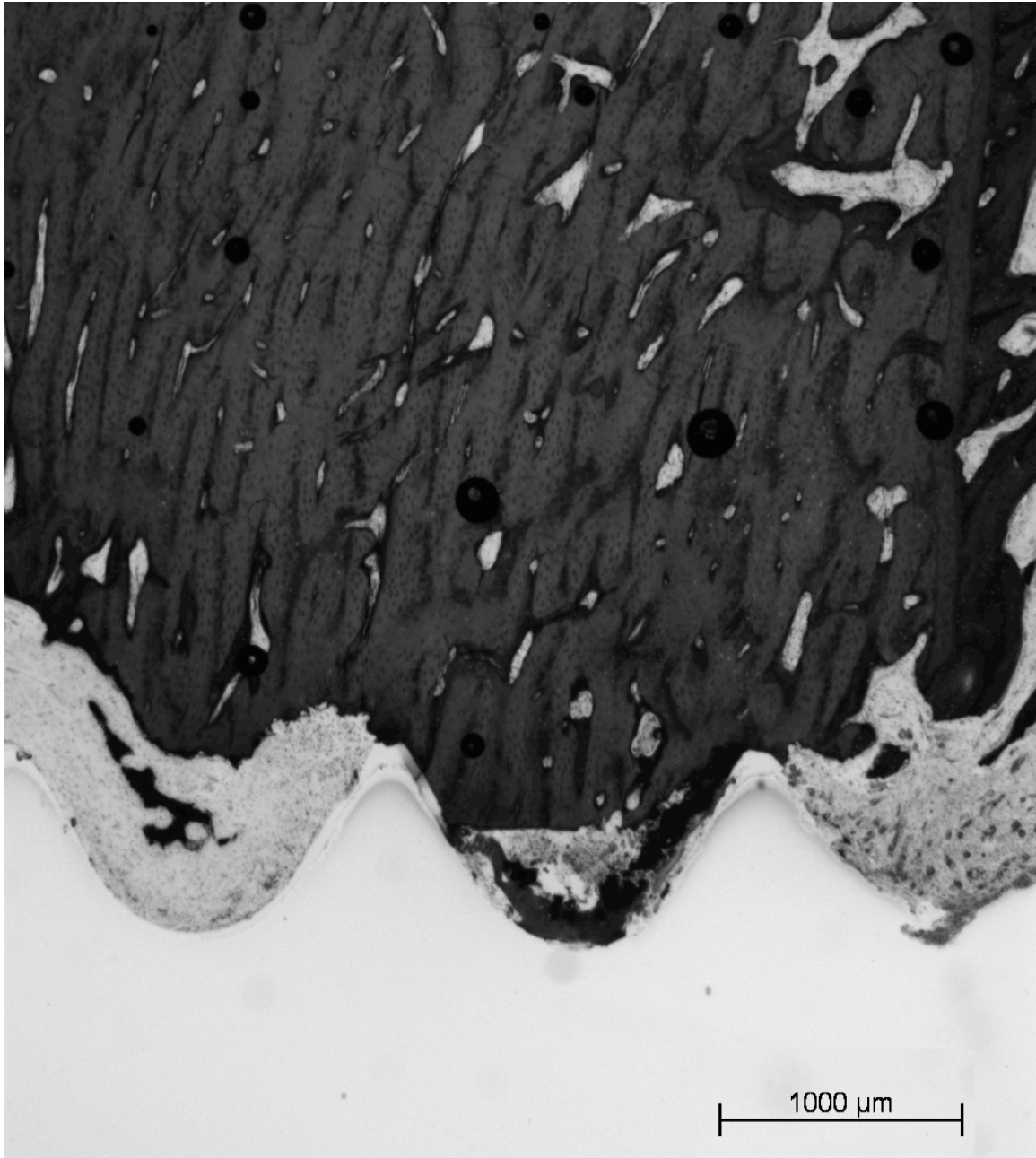


Figure 11.b Histology of distal TP implant. Photomicrograph of a non-decalcified specimen, stevenol blue stain. Interface index score of 3 (only fibrous tissue contact). During processing the implant fell out of the specimen after it was cut and before it was embedded in methylmethacrylate.

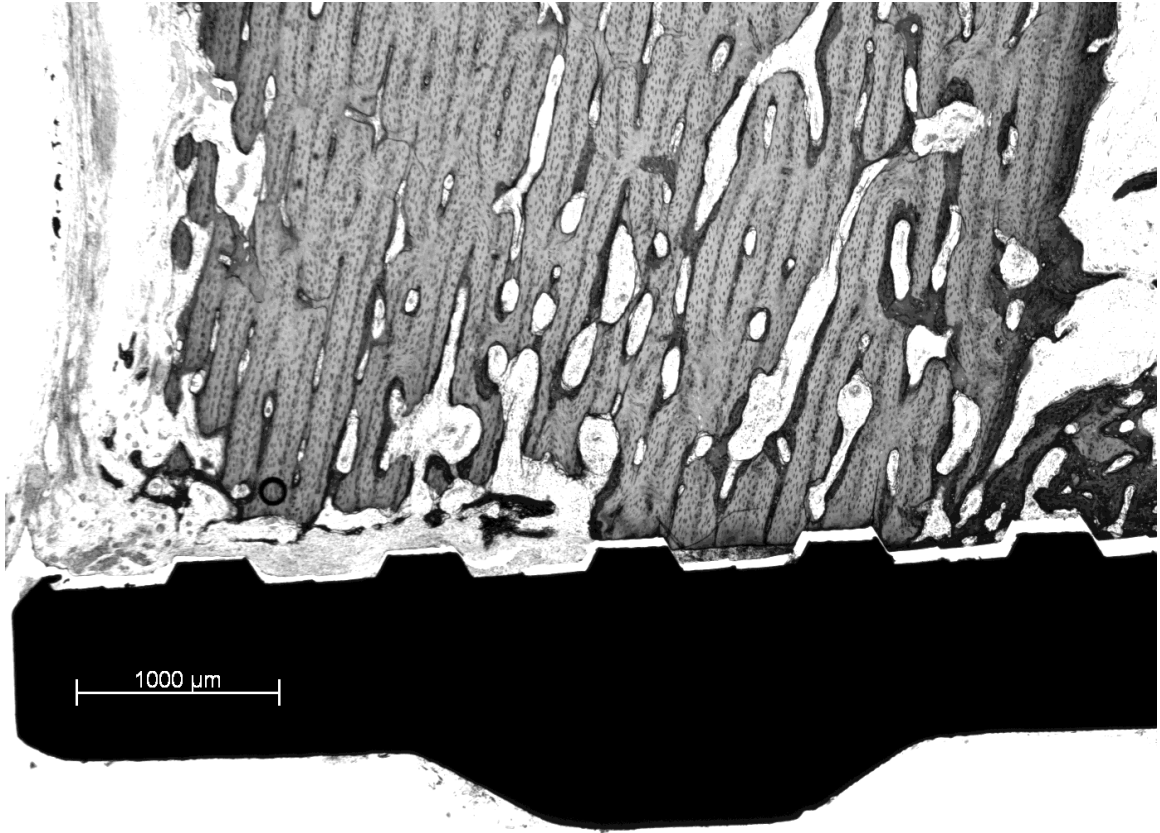


Figure 12.a. Histology of proximal PS implant. Photomicrograph of a non-decalcified specimen, stevenol blue stain. Interface index score of 2 (intermittent contact of fibrous tissue and bone).

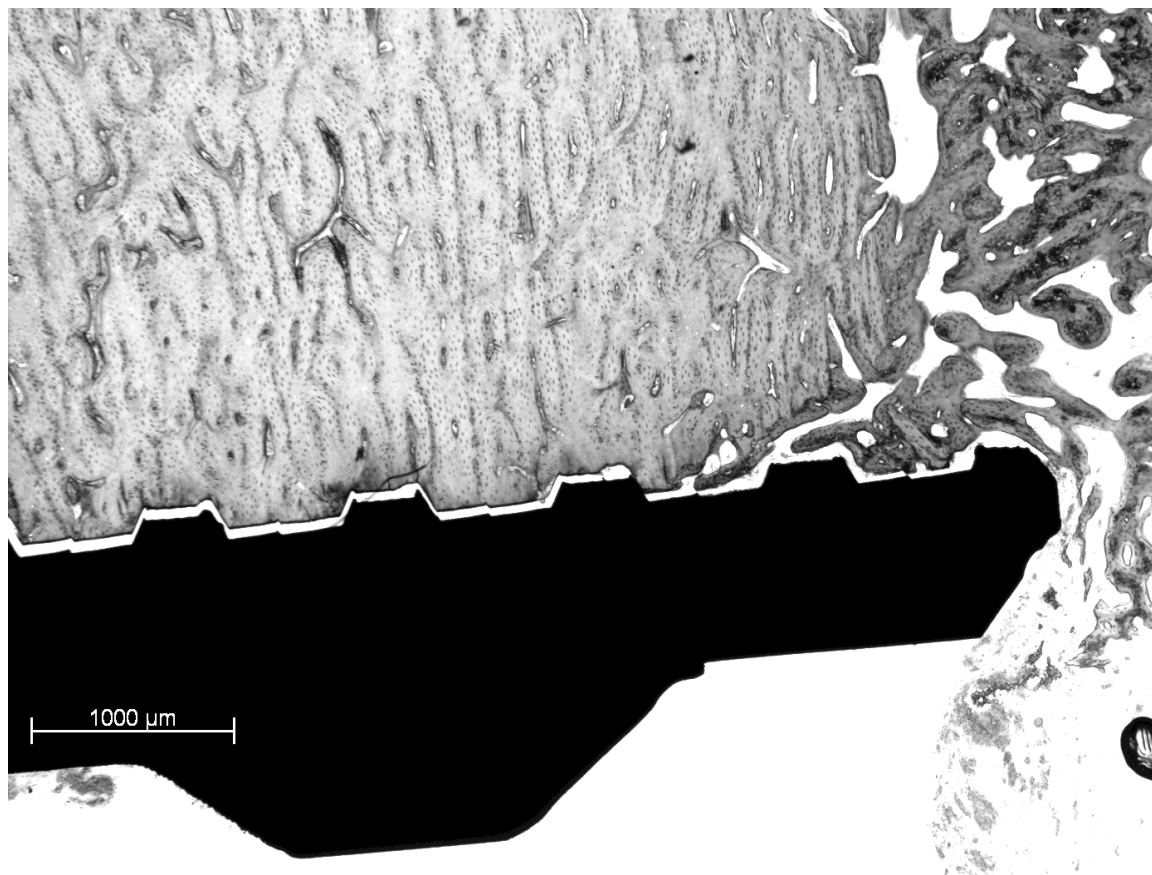


Figure 12.b. Histology of distal PS implant. Photomicrograph of a non-decalcified specimen, stevenol blue stain. Interface index score of 0 (direct cortical contact). Bone ingrowth around the extremity of the implant is visible.

All calves tolerated the fluorochrome administration well. No adverse reactions seen. The day following calcein green administration, fluorescent green urine was noted. Within 15 minutes of beginning the alizarin complexon infusion, dark purple urine was observed, and feces passed the following day were dark mauve. The fluorochrome labels marked periosteal and endosteal new bone growth, but did not indicate peri-implant remodeling in either TP or PS calves.

One TP calf was euthanized at day 18 for pain non-responsive to medical management including butorphanol and NSAID administration and a cast change. This calf had radiographic and histologic evidence of osteomyelitis (Figure 13). Its results are included in the data.

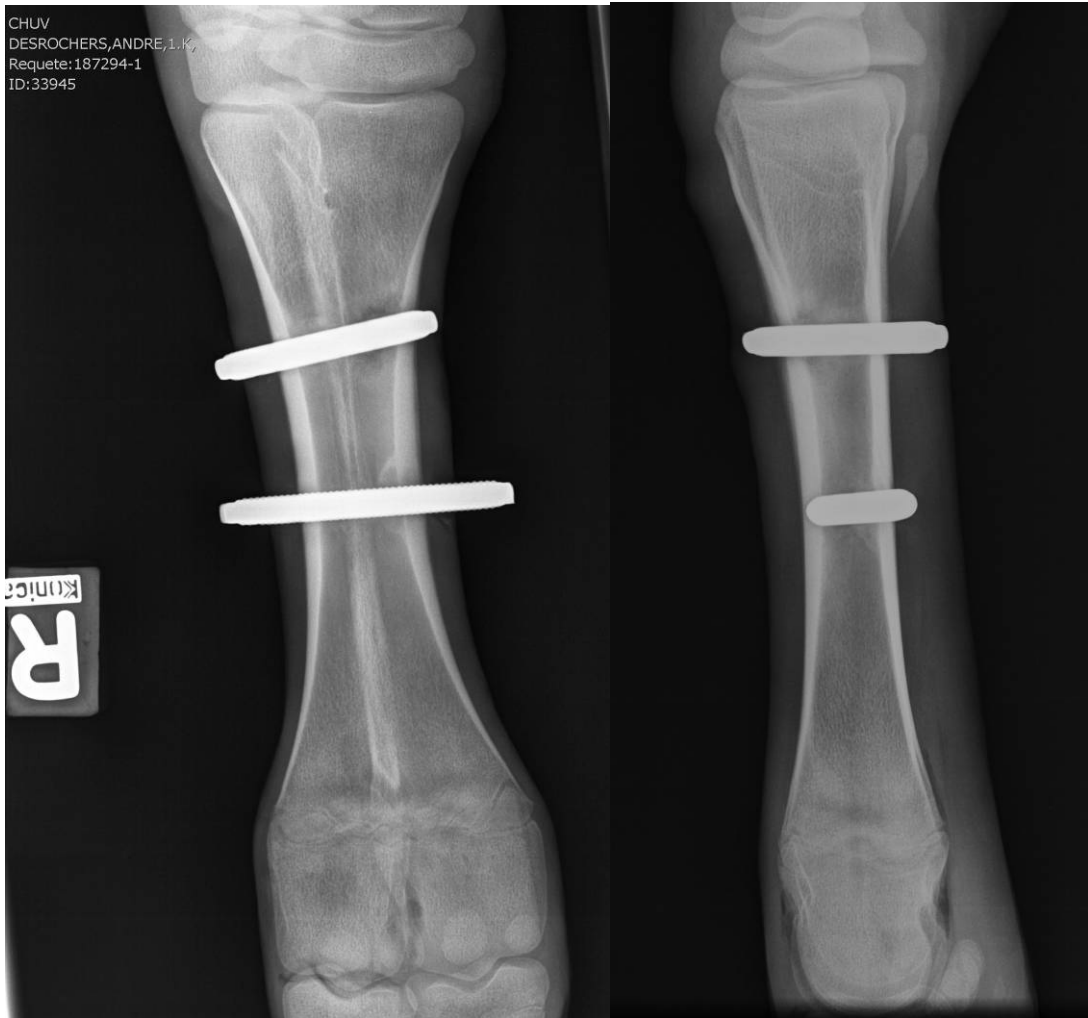


Figure 13.a. Radiographs of calf euthanized at day 18. Dorso-plantar and lateral radiographs of the calf euthanized for pain non-responsive to opioid and NSAID administration and a cast change. A radiolucent zone of osteomyelitis is visible near the medial endosteal surface of the proximal implant.

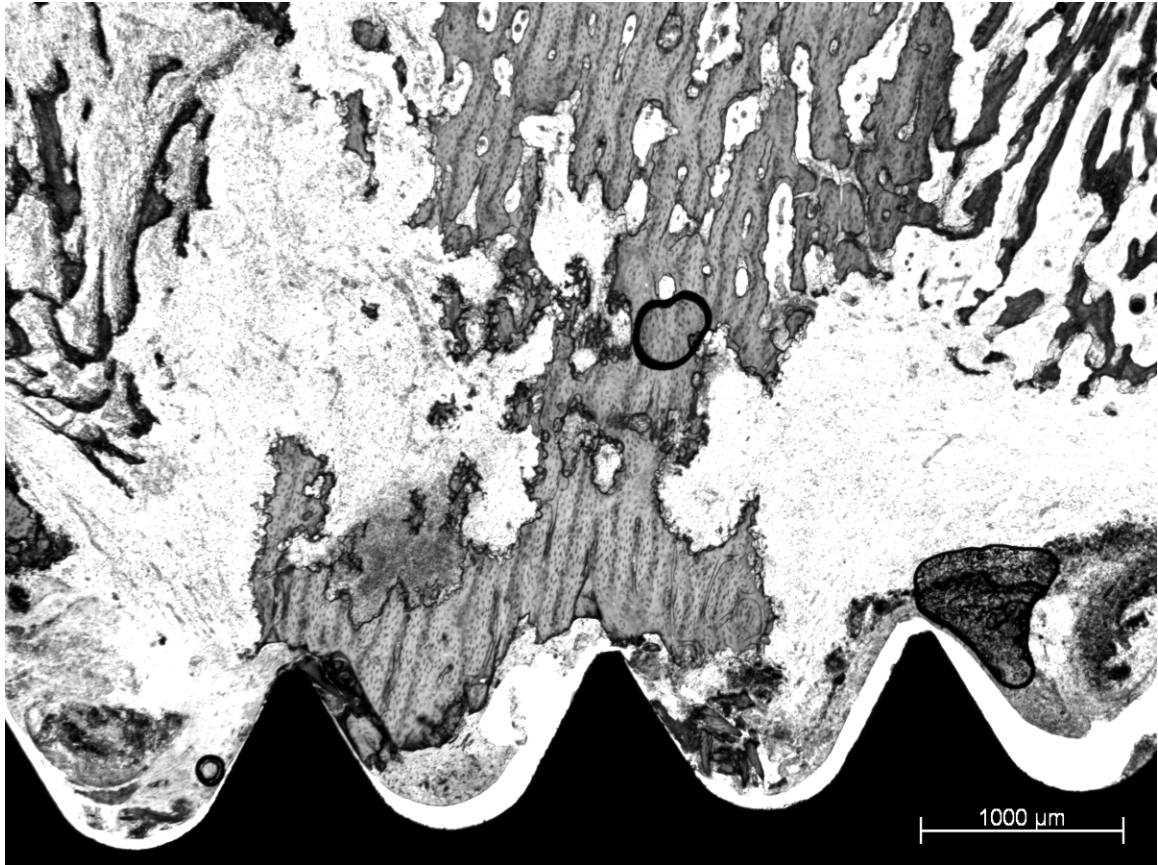


Figure 13.b. Histology of calf euthanized at day 18. Photomicrograph of a non-decalcified specimen, Stevenol blue stain. Zone 3 of the proximal implant of the calf euthanized for pain non-responsive to opioid and NSAID administration and a cast change. There is marked cortical destruction around the implant; the scalloped borders from osteoclastic resorption are visible. The debris in the background is bacteria and inflammation from the infection. Note the almost non-existent bone-implant interface, this was graded 4 (inflammation around the implant) on our interface index scale. An air bubble from processing is visible in the middle of the image.

## DISCUSSION

This study demonstrates histologically and radiographically the changes that occur around pins as they loosen in TP and shows that a novel PS system has the potential to decrease the morbidity associated with pin loosening. Previous studies have focused on pin configuration, implant coatings and orientation in *ex vivo* models to maximize the strength TP. While improvements have been made, the root of the problem persists: the bone-pin interface. The PS system eliminates the bone-pin interface that is subject to cyclic loading and micromotion by creating a theoretically immobile bone-implant interface.<sup>9</sup>

The calf model was judiciously chosen in this study because of its long bone characteristics. Long bones in calves have relatively thin cortices, which provide for minimal bone-implant contact.<sup>20</sup> At birth, a calf's skeleton is mostly composed of woven bone.<sup>21</sup> The woven nature of the bone provides an environment where the thin cortices do not allow adequate holding power of implants and thus permit premature implant loosening and subsequent motion at the fracture site.<sup>22</sup> Woven bone, with its randomly arranged collagen fibers, is inferior in strength to lamellar bone, which has regularly arranged fibrils of collagen.<sup>23</sup> A neonatal calf model was selected for this study because of the bones' thin cortices and potentially faster lysis at the bone-implant interface.

As cortices are subjected to repetitive loading while walking, osteolysis and necrosis occur leading to implant loosening. This activates nociceptors in the periosteum causing pain for the patient and instability at the fracture site.<sup>11</sup> The PS system caused minimal osteolysis and had near-perfect bone implant contact when implanted in diaphyseal bone. The TP implants caused extensive osteolysis regardless of location. The earlier increase in lameness of TP calves is attributed to this osteolysis and subsequent pin loosening and associated pain.

The results of this study contain data from the TP calf that was euthanized at day 18 due to pain that was non-responsive to medical treatment. No bacterial culture was taken because the infection was located inside of the bone and drainage was not observed



at the cast change or euthanasia. The results from this animal were included in the study because pin tract infection and osteomyelitis are clinically relevant complications, and we felt it was of the utmost importance to report such complications.

This study was originally begun with a pilot group of calves, that underwent distal diaphyseal osteotomy before cast application with only double layer stockinette padding (data not reported). An incredible amount of cast disease and deep ulceration to the underlying bone and delamination of the claws was seen by the end of the 28-day study. These complications were attributed to post-operative swelling under the cast. Despite these devastating results, the pilot calves rarely had elevated heart rates, had excellent appetites and were regularly observed ruminating. From that point on, the study was completed without the osteotomy and cast padding with Delta-Dry and yellow foam. The pain scoring system used in this study appears to accurately reflect peri-implant osteolysis, but appears to be less sensitive to predicting cast disease.

The radiographic measurements obtained support the differences seen histologically between proximal and distal implants. While there were no differences in cortical thickness above or below the distal implant in either group, the proximal implant was situated in bone with significantly thinner proximal cortices. When considering this finding with the knowledge that the proximo-external and disto-internal cortices of an implant are where the load is centered during weight bearing<sup>9,11</sup>, it is no surprise that extensive osteolysis was seen histologically, as there was a minimal amount of cortical bone to support either proximal implant.

Based on our clinical, radiographic and histomorphometric results, this novel PS system creates significantly less peri-implant osteolysis when in diaphyseal bone. The osteolysis seen around the proximal implant could be explained by the following possibilities. First, it has already been reported that the proximal implant of this system and the proximal transfixation pin in a walking bar system are subject to much greater loads than distal implants.<sup>9,24</sup> So it is possible that regardless of the type of implant, osteolysis would have occurred. However, the next distal implant is subjected to load bearing and transfer to the cast or sidebar, just less than the proximal implant. In the TP

calves, osteolysis similarly extensive and severe was seen around the distal implant as well as the proximal implant. When tested on the computer model, the distal pin-sleeve implant and surrounding bone were less stressed than the proximal, but both locations showed a significant decrease in axial strain on the bone compared to the transfixation pins.<sup>9</sup>

Secondly, the cancellous nature of metaphyseal bone does not provide a solid cortical bone-implant interface. McClure et al. concluded that the greatest axial resistance to extraction was when the pins were situated in diaphyseal, not metaphyseal, bone.<sup>25</sup> The proximal metaphyseal-diaphyseal junction where the proximal implants were situated is unsuitable bone for either system. As was predicted by the *in vitro* and finite element analyses of the equine PS system, very little osteolysis was observed when the PS system was instrumented in solid cortical bone. The capacity of this system to more evenly redistribute load to the cortical bone lies in the surgeon's ability to implant it into a solid cortex and center the rims on the cortex.

This study has multiple unique facets. First, all calves underwent multimodal, field-applicable anesthesia and pain control consisting of sedation, brachial plexus nerve block, systemic NSAID administration, and nasal oxygen during pin placement. We feel that brachial plexus anesthesia is adequate for orthopedic procedures involving the thoracic limb and have since used this technique with success on clinical cases in calves and adults. Secondly, this study evaluates the peri-implant biological behavior of bone in TP. Other reported studies of TP in large animal orthopedics tested pin size, coating and orientation; reported biomechanical, not *in situ* histological, measures of pullout strength and removal torque; or are retrospective in nature.<sup>4-7,26-30</sup>

Surgery times decreased with experience; the first surgeries lasted 1 hour, and the last surgeries were completed in 30 minutes. The drill sleeve guides permitted accurate and rapid drill bit placement with each drill bit change and provided excellent soft tissue protection. Cast removal for the PS calves was important to complete sequentially as described. Otherwise, attempts at cutting through detached pieces of cast material (i.e. the band between the two rings once all of the circumferential cuts had been made) seemed

to only vibrate the cast material instead of cutting it. The extra padding also allowed for the expansion of the limb due to normal growth and permitted the limb to be immobilized for 4 weeks. At the time of cast removal, small circles of discoloration were interpreted as the beginning of cast disease. Therefore, regardless of the amount of padding used, we agree with the current recommendations to not immobilize of the limb of a young, growing animal for longer than 3 weeks without changing the cast.<sup>8</sup> Skin surface pressure under casts has been studied in human medicine.<sup>31-33</sup> Lower skin surface pressures were found under plaster casts than fiberglass casts.<sup>32</sup> However, given the size and weight of large animal patients, the increased strength of a fiberglass cast is imperative. Therefore adequate padding and surveillance for continued comfort are important in managing casted limbs of animals, adults and neonates alike.<sup>34</sup>

We hypothesize that the absence of fluorochrome uptake around the implants was due to one of two extremes: either there was so much peri-implant osteolysis and instability that no new bone could be made or that the implants without osteolysis were so stable that new bone-formation was unnecessary. In studies utilizing fluorochromes, some form of bone cement or implant coating is used and therefore a peri-implant space is provided for osseous in-growth, which could be labeled if a fluorochrome was given at the appropriate time.<sup>18,35,36</sup> The presence of the fluorochromes in the endosteal growth confirms that appropriate dosages and routes of administration were used in the current study.

Because this project was conducted on a small number of neonatal calves, more investigations are necessary to determine the biological behavior of bone around the PS system in other species and in older animals. For these situations, varying lengths of sleeves, pins and diameter rings would need to be manufactured. Some in-growth of the bone around the sleeve edges was observed histologically. Since we did not try to remove any sleeves, we are unable to predict how this could affect sleeve removal, but in all likelihood would make it much more challenging. In the papers reporting the adult version of the pin-sleeve system, it was suggested that the sleeve could be left in the bone after cast removal.<sup>9,11</sup>

Despite the small number of test subjects, convincing evidence was gathered that support the pin-sleeve system's potential use in the clinical setting. For some animals and some fractures, a traditional TP is sufficient. However, for young animals with extremely soft bone and for larger or older animals with extremely comminuted fractures where healing times will be prolonged, this novel pin-sleeve and ring system provides the possibility to minimize implant loosening, maximize patient comfort and change casts as needed without disrupting the implant-bone interface when implanted in diaphyseal bone.

**REFERENCES**

1. Aithal HP, Amarpal, Kinjavdekar P, et al. Management of fractures near the carpal joint of two calves by transarticular fixation with a circular external fixator. *Vet Rec* 2007;161:193-198.
2. Anderson DE, St-Jean G, Richardson DC, et al. Improved osseointegration of calcium phosphate-coated external fixation pins. Studies in calves. *Acta Orthop Scand* 1997;68:571-576.
3. Kaneps AJ, Schmotzer WB, Huber MJ, et al. Fracture repair with transfixation pins and fiberglass cast in llamas and small ruminants. *J Am Vet Med Assoc* 1989;195:1257-1261.
4. St-Jean G, Clem MF, DeBowes RM. Transfixation pinning and casting of tibial fractures in calves: five cases (1985-1989). *J Am Vet Med Assoc* 1991;198:139-143.
5. St-Jean G, Debowes RM. Transfixation pinning and casting of radial-ulnar fractures in calves: A review of three cases. *Can Vet J* 1992;33:257-262.
6. Lescun TB, McClure SR, Ward MP, et al. Evaluation of transfixation casting for treatment of third metacarpal, third metatarsal, and phalangeal fractures in horses: 37 cases (1994-2004). *J Am Vet Med Assoc* 2007;230:1340-1349.
7. Nash RA, Nunamaker DM, Boston R. Evaluation of a tapered-sleeve transcortical pin to reduce stress at the bone-pin interface in metacarpal bones obtained from horses. *Am J Vet Res* 2001;62:955-960.
8. Anderson DE, St Jean G. External skeletal fixation in ruminants. *Vet Clin North Am Food Anim Pract* 1996;12:117-152.
9. Brianza S, Brighenti V, Lansdowne JL, et al. Finite element analysis of a novel pin-sleeve system for external fixation of distal limb fractures in horses. *Vet J* 2010.
10. Crawford WH, Fretz PB. Long Bone Fractures in Large Animals: A Retrospective Study. *Vet Surg* 1985;14:295-302.

11. Brianza S, Brighenti V, Boure L, et al. In vitro mechanical evaluation of a novel pin-sleeve system for external fixation of distal limb fractures in horses: a proof of concept study. *Vet Surg* 2010;39:601-608.
12. Brianza S, Vogel S, Rothstock S, et al. Comparative notch effect evaluation for the removal of two different implants for distal limb fracture in large animals. *Vet Surg* 2011;Submitted.
13. Brianza S, Vogel S, Rothstock S, et al. Ex vivo evaluation of the pin-sleeve system. *Vet Surg* 2011;Under revisions.
14. Hamilton GF, Tulleners EP. Transfixation pinning of proximal tibial fractures in calves. *J Am Vet Med Assoc* 1980;176:725-727.
15. Katz JL, Misra A, Spencer P, et al. Multiscale mechanics of hierarchical structure/property relationships in calcified tissues and tissue/material interfaces. *Mater Sci Eng A Struct Mater* 2007;27:450-468.
16. Francoz D, Desrochers A, Fecteau G, et al. Synovial fluid changes in induced infectious arthritis in calves. *J Vet Intern Med* 2005;19:336-343.
17. Estebe JP, Le Corre P, Chevanne F, et al. Motor blockade by brachial plexus block in the sheep. *Anesthesiology* 2000;93:291-293.
18. Stadlinger B, Lode AT, Eckelt U, et al. Surface-conditioned dental implants: an animal study on bone formation. *J Clin Periodontol* 2009;36:882-891.
19. Jansen JA, van der Waerden JP, Wolke JG. Histological and histomorphometrical evaluation of the bone reaction to three different titanium alloy and hydroxyapatite coated implants. *J Appl Biomater* 1993;4:213-219.
20. Blikslager AT, Bowman KF, Abrams CF, Jr., et al. Holding power of orthopedic screws in the large metacarpal and metatarsal bones of calves. *Am J Vet Res* 1994;55:415-418.
21. Young B, Heath J. Skeletal Tissues In: Young B, Heath J, eds. *Wheaters Functional Histology*. Edinburgh: Churchill Livingstone, 2002;175-188.
22. Ames NK. Comparison of methods for femoral fracture repair in young calves. *J Am Vet Med Assoc* 1981;179:458-459.
23. Martin RB, Ishida J. The relative effects of collagen fiber orientation, porosity, density, and mineralization on bone strength. *J Biomech* 1989;22:419-426.

24. Nunamaker DM, Richardson DW, Butterweck DM, et al. A new external skeletal fixation device that allows immediate full weight bearing: application in the horse. *Vet Surg* 1986;15:345-355.
25. McClure SR, Hillberry BM, Fisher KE. In vitro comparison of metaphyseal and diaphyseal placement of centrally threaded, positive-profile transfixation pins in the equine third metacarpal bone. *Am J Vet Res* 2000;61:1304-1308.
26. Hopper SA, Schneider RK, Ratzlaff MH, et al. Effect of pin hole size and number on in vitro bone strength in the equine radius loaded in torsion. *Am J Vet Res* 1998;59:201-204.
27. McClure SR, Watkins JP, Ashman RB. In vitro comparison of the effect of parallel and divergent transfixation pins on breaking strength of equine third metacarpal bones. *Am J Vet Res* 1994;55:1327-1330.
28. McClure SR, Watkins JP, Bronson DG, et al. In vitro comparison of the standard short limb cast and three configurations of short limb transfixation casts in equine forelimbs. *Am J Vet Res* 1994;55:1331-1334.
29. Zacharias JR, Lescun TB, Moore GE, et al. Comparison of insertion characteristics of two types of hydroxyapatite-coated and uncoated positive profile transfixation pins in the third metacarpal bone of horses. *Am J Vet Res* 2007;68:1160-1166.
30. Anderson D, Silviera F. Effect of pin size and pin tract osteolysis on removal torque of positively threaded transfixation pins used in external skeletal fixation in cattle: a prospective study. *World Buiatrics Congress*. Santiago, Chile, 2010.
31. Garfin SR, Mubarak SJ, Evans KL, et al. Quantification of intracompartmental pressure and volume under plaster casts. *J Bone Joint Surg Am* 1981;63:449-453.
32. Marson BM, Keenan MA. Skin surface pressures under short leg casts. *J Orthop Trauma* 1993;7:275-278.
33. Uslu MM, Apan A. Can skin surface pressure under a cast reveal intracompartmental pressure? *Arch Orthop Trauma Surg* 2000;120:319-322.
34. Swaim SF, Vaughn DM, Spalding PJ, et al. Evaluation of the dermal effects of cast padding in coaptation casts on dogs. *Am J Vet Res* 1992;53:1266-1272.

35. Hirvinen LJ, Litsky AS, Samii VF, et al. Influence of bone cements on bone-screw interfaces in the third metacarpal and third metatarsal bones of horses. *Am J Vet Res* 2009;70:964-972.
36. Niehaus AJ, Anderson DE, Samii VF, et al. Effects of orthopedic implants with a polycaprolactone polymer coating containing bone morphogenetic protein-2 on osseointegration in bones of sheep. *Am J Vet Res* 2009;70:1416-1425.
37. Bicalho RC, Cheong SH, Cramer G, et al. Association between a visual and an automated locomotion score in lactating Holstein cows. *J Dairy Sci* 2007;90:3294-3300.



**FOOTNOTES**

- a. Stimuplex A, 0.9 x 150 mm, Braun, Melsungen, Germany
- b. Centerface Transfixation Pin, part 2141LA, IMEX Veterinary Inc, Longview, TX USA
- c. DigiTorque wrench, PB Swiss Tools, Bern, Switzerland
- d. Nonpermanent Thread Locker, Canadian Tire, St-Hyacinthe, QC Canada
- e. Delta-Dry cast padding, Ref 73443-01, BSN Medical, Brierfield, England
- f. 3M Custom Support Foam, 3M, St. Paul, MN USA
- g. Delta-Lite Plus, Ref 73458-00002-00, BSN Medical, Brierfield, England
- h. Calcein green, C0875, Sigma-Aldrich Canada Ltd, Oakville, ON Canada
- i. Alizarin Complexone, A3882, Sigma-Aldrich Canada Ltd, Oakville, ON Canada
- j. Agfa HealthCare Corporation, Greenville, SC USA
- k. Zeiss Axio Imager 2 microscope & AxioVision 4.6 software, Carl Zeiss Canada Ltd., Toronto, ON Canada

## Discussion

This project was a unique opportunity to perform the clinical trial of a novel orthopedic implant that addresses commonly encountered problems with external fixation differently from previously published studies. Using TP as the control, the PS system was evaluated clinically, radiographically, and histologically in a calf model. Neonatal calves were specifically chosen as a model because the biological and mechanical properties of their long bones permit evaluation of accentuated peri-implant osteolysis relatively quickly.

For the majority of studies testing orthopedic implants, *in vitro* or *ex vivo* results are reported and therefore it is impossible to assess the biological reaction of the bone over time.[3, 35, 36, 39, 42, 50, 64, 67-72] Other *in vivo* studies have measured pull-out or push-out strength and removal torque to quantify implant loosening.[11, 12] In the study by Anderson et al. comparing hydroxyapatite-coated and non-coated pins in a type II ESF in a calf model, no significant differences were found with yield stress and peak force between the groups while significant differences were found on the histomorphometric analysis after 40 days.[11] In another study on sheep with two different versions of type I ESF, no pin loosening was noted after 9 weeks.[73] However, adult sheep were used in that study and all pins were located throughout the diaphysis. In the present study, peri-implant osteolysis was seen clinically as limb unloading and increased pain scores beginning at 3 weeks and was evident histologically at 4 weeks.

Given the soft nature of calf bones and the results of Anderson et al.'s study, we chose to examine the biological reaction of bone to two types of ESF with transfixation casting in order to have the most detailed information possible of the bone-implant interface. Their results showed an important difference in radiographic evidence of osteolysis between coated and uncoated pins.[11] The measurements taken from the radiographs in this study did not show a significant difference in cortical thickness between the TP and PS groups. If osteolysis was present, it should manifest itself by smaller cortices. It is possible that our methods of measurement were too specific and therefore contained too much variability in the data to show a significant difference. But when each

implant in each calf is considered (10 implants per group), then 10/10 TP implants (n = 5 calves) and 3/10 PS implants (n = 3 calves) had radiographic evidence of osteolysis. All PS implants were proximal implants. These results were significant.

This study began with a pilot group of six animals, three with TP and three with PS, (materials and methods in Appendix A). The original experimental design was to create a 30° oblique osteotomy in attempt to recreate a clinical situation of an unstable fracture. The limbs were subsequently padded with a double layer stockinette and casted. In these six animals, only one did not have any cast disease. In the other five animals, erosions over the dorsal surfaces of the medial and lateral metacarpo-phalangeal and proximal interphalangeal joints were so severe that the underlying bones were exposed. One animal has bruising noted around the coronary bands of both casted claws. During gentle digital palpation, both hooves fell off in the examiner's hands exposing purple, bruised corium. These five calves were male and had varying degrees of fracture healing, but fracture callous was present in each osteotomy site. The sixth animal with no cast disease was a female, had similar weight gain patterns to the male calves, and had no fracture callous or periosteal proliferation.

These results of devastating cast disease were unforeseen, and after reflection, were attributed to marked swelling underneath the casts. Upon further review of the literature, there are no *in vivo* tests of osteotomized and casted limbs. Any information about the stability of fracture fragments in TP is from *ex vivo* models.[3, 67, 72] And those reports that utilize an osteotomy or ostectomy in live animals are reporting on type I or II ESF, where any post-operative swelling would be uninhibited by a cast. [11, 12, 53, 73] When animals, in a clinical setting, are presented with fractures, the swelling has already occurred and, therefore an already swollen leg is casted. Whereas in our pilot group, osteotomized, non-swollen limbs were casted, and no space or padding was provided to accommodate for swelling.

In consideration of these results, the experimental model was modified. First, no osteotomy was created. Secondly, in lieu of double layer stockinette, one layer of Delta-Dry cast padding and yellow foam cast padding were applied to each limb before casting. Although this model does not stimulate the clinical situation of an unstable fracture, it eliminated the problems seen in the pilot group and provided a great deal of comfort for the calves. With only having a casted leg and no associated pain from an osteotomy or swelling, the animals loaded their limbs more evenly and thus would have been able to create peri-implant osteolysis to a greater degree if it were to happen at all. Lastly, the value of one or two pilot animals was appreciated. These problems would have likely been identified and corrected using less animals and therefore minimizing animal suffering while in the end using fewer research animals, saving time, resources and research funds.[14]

The extra padding also allowed for the expansion of the limb due to normal growth and permitted the limb to be immobilized for 4 weeks. At the time of cast removal, small circles of discoloration were noted over the same sites as the pilot group. These were interpreted as the beginning of cast disease. Therefore, regardless of the amount of padding used, we do not recommend cast immobilization of the limbs of young, growing animals for longer than 3 weeks without changing the cast. Skin surface pressure under casts has been studied in human medicine, but only one report was found from veterinary medicine. [45, 59, 74, 75] Lower skin surface pressures were found under plaster casts than fiberglass casts.[59] However, given the size and weight of large animal patients, the increased strength of a fiberglass cast is imperative. Therefore adequate padding and surveillance for continued comfort are important in managing casted limbs of animals, adults and neonates alike.[45]

Static force plate analysis was also performed on all calves to more objectively measure comfort and loading or unloading of the limbs (materials, methods and results in Appendix B).[14] It was nearly impossible to train these calves to walk at a constant speed without jerking or jumping motions so dynamic force plate analysis was not an option. However, it was relatively easy to get them to remain standing on a static force plate while

suckling the nipple of a calf bottle that was at a fixed height, centered in front of the forceplate. Based on clinical observation and pain scores, there was no correlation between the force plate and lameness scores, but those animals that unloaded their limbs sooner and to a greater percentage had more cast related problems. This observation was the most obvious with the aforementioned pilot group. One challenge of using calves as test subjects is their stoic nature. Even when cast sores eroded into articulations and the animals were non-weight bearing when stationary, their lameness scores were not severe, their appetites were excellent, and they were regularly observed ruminating. The lameness and pain scores seem to be more accurate in predicting implant loosening and infection than cast disease.

Both systems were successfully implanted and well-tolerated by the calves. Surgery using sedation and brachial plexus block permitted instrumentation of orthopedic devices in calves without general anesthesia. This technique was first reported in sheep, and has since been modified in our teaching hospital for routine use in farm animal patients.[76, 77] After surgery, the calves were able to stand and walk on the limb within 2 hours. Aside from a transient, nonpainful swelling in one animal just cranial to the scapulo-humeral joint, no other minor or major complications were observed using the brachial plexus block technique. This local motor blockade provided effective and inexpensive regional anesthesia.

No catastrophic failure of the bones or implants was observed. One calf was euthanized at day 18 because of pain nonresponsive to opioids, NSAIDs and a cast change. This calf had radiographic and histologic evidence of osteomyelitis. No bacterial culture was taken because the infection was located inside of the bone and drainage was not observed at the cast change or euthanasia. The results from this animal were included in the study because pin tract infection and osteomyelitis are clinically relevant complications, and we felt it was of the utmost importance to report such complications.[32] Not including the aforementioned calf, pin tract infections were noted histologically in 4 of 8 TP pins and 2 of 10 PS sleeves. These infections were contained to the cortical threads and periostium of the implants. Reports including local infection or drainage are common with external

fixation.[11, 12, 28, 30, 31, 43, 56] In a clinical report of horses with TP, 5 of 29 animals fractured through a pinhole, one of which was attributed to severe osteomyelitis.[28] It is likely that the prolonged periods normally spent in recumbency by cattle and their ability to stand comfortably on 3 limbs helped to prevent catastrophic failure seen in equine patients.[17] Aside from the delamination of the casted claws of one pilot calf, no laminitis was appreciated in the other calves.

The absence of fluorochrome markers around the implants was a disappointing finding. In the published studies using fluorochromes in live animals, the projects were evaluating implant coatings.[8-10] Coated implants with biocompatible coatings are made for osseointegration. Therefore the most specific measure of success of a coating would be osseous ingrowth down to the implant. Fluorochrome markers would highlight is ingrowth and help determine the timeline for the bone production. However, when no coating is present, there is no place for new bone to grow; this was the case in the present study. Due to the extreme differences of peri-implant osteolysis between the TP and the PS systems and proximal and distal implants, two hypotheses seem probable to explain the results. When peri-implant osteolysis was present, it was so severe and on going that no new bone growth around the implant was possible and no fluorochrome markers were seen. When there was no osteolysis present, there was no place for new bone to form because the implants were seated in the cortical bone with a solid-bone implant interface.

Additionally, the previously reported studies were completed with non-weight bearing implants and the frequency of fluorochrome administration varied. When non-weight bearing implants are tested, there may not be osseointegration, but there is also a lower probability of peri-implant loosening because the implants are not loaded. Lastly, when the same fluorochrome is repeatedly administered, it is more likely that it will be detected microscopically, but it is impossible to determine the timeline of new bone formation because of repeated use of the same marker. The presence of the markers in the periosteal and endosteal new bone growth of our specimens verifies that appropriate doses

and routes of administration were used and seems to support the previously proposed hypotheses.

In the articles by Brianza et al. [40, 51] the possibility of leaving the sleeves in place was briefly mentioned. If there is no infection around the implant, this could be a biomechanically superior choice to removing the sleeve. If the sleeve is left in place, then the stress riser that is created by the defect after implant removal would diminish. In a study on pig femurs that examined the effect of a bicortical 4mm hole on bone strength, they found that by filling the hole (with a screw or with plaster of paris), there was an increase in bone strength compared to unfilled holes.[37] Although further tests are needed to confirm or disprove this theory, one could argue that the sleeve left in a healed bone would perform the same function as the screw or plaster of paris in the study by Ho et al.[37] Secondly, in growing animals, eventually the sleeve would be encased in the medullary cavity and there would be no cortical defect. The long-term results of this scenario are unknown.

Other considerations for the sleeves in the PS system are their length and the location of the contact rim. The current study used 30 mm long sleeves for the proximal site and 27 mm long sleeves for the distal. When the calves were larger, the sleeves did not always traverse the entire length of the cortex. And in the smaller calves (i.e. the jersey calves), the distal sleeve was too long. These situations created the same problem: the rim is not centered on the cortex; therefore, the distribution of the forces to the cortex is suboptimal. We believe that this explains some of the osteolysis seen at the proximal PS implants. Also occurring both with normal growth and short implants, the periosteum and cortical bone begin to grow into the sleeve. If the sleeves were to be removed after fracture healing, a specialized cutting instrument may be necessary to free the sleeve since the sleeve itself has no cutting edge or threads.

Based on our clinical, radiographic and histomorphometric results, the novel PS system creates significantly less peri-implant osteolysis when in diaphyseal bone compared to TP. The osteolysis seen around the proximal implant could be explained by the following

possibilities. First, it has already been reported that the proximal implant of this system and the proximal transfixation pin in a walking bar system are subject to much greater loads than distal implants.[33, 40] So it is possible that regardless of the type of implant, osteolysis would have occurred. However, the next distal implant is subjected to load bearing and transfer to the cast or sidebar, just less than the more proximal implant. In the TP calves, osteolysis similarly extensive and severe was seen around the distal implant as the proximal implant. When tested on the computer model, the distal PS implant and surrounding bone were less stressed than the proximal, but both locations showed a significant decrease in axial strain on the bone compared to the TP.[40]

Secondly, the cancellous nature of metaphyseal bone may not provide a solid bone-implant interface. McClure et al. compared the tensile force at failure for axial extraction in adult equine bones for positive profile, centrally threaded pins.[42] They concluded that the greatest axial resistance to extraction was when the pins were situated in diaphyseal bone. Our results of the PS system being more solidly seated in diaphyseal bone compared to metaphyseal bone are similar to those of McClure. However, in the equine literature, which accounts for the bulk of information regarding TP, it is not recommended to put the pins any more proximal than the distal diaphysis otherwise there is a great risk of fracture through a pinhole.[28] The location of the TP and PS implants at the metaphyseal-diaphyseal junction is one of the major weaknesses of this study. Had both proximal and distal implants been located in diaphyseal bone, a more objective comparison would be possible. Instead, the conclusion that is drawn is that the metaphyseal bone of calves is inadequate for either implant system.

When inserting transcortical implants that are 6 to 9 mm in diameter an adequate amount of bone between each implant must be left. It is extremely difficult to not seat at least one implant in metaphyseal bone or at the metaphyseal-diaphyseal junction. In bovine patients more proximally placed pins in the metacarpus/tarsus for distal metacarpal/tarsal fractures are tolerated without catastrophic failure, but given the location of a comminuted fracture requiring external fixation, there, too, is the situation where implantation in



metaphyseal bone is nearly unavoidable. The other option would be to implant the system in the distal diaphysis of the tibia or radius and place a full limb cast. Larger rings and longer implants would be mandatory for this scenario. In equine patients implants are placed in the distal metacarpus/tarsus for comminuted phalangeal fractures. With this location, the proximal implant is in the distal diaphysis and the distal implant in the distal diaphyseal-metaphyseal junction or metaphysis. In this situation, maybe the distal metaphyseal location of the implant is of less consequence than the location of implants in this study because the more solid diaphyseal bone would take the majority of the load with the proximal implant. Interestingly, although the mid-diaphysis of equine metacarpal and metatarsal bones are rarely implanted with transfixation pins for TP, this is the location for biomechanical *ex vivo* tests.[35, 69, 71]

Given the significant difference in the radiographic and histological results of the proximal and distal PS implants, one of the major limitations, in hindsight, is the choice of implant location. These locations were chosen based on clinical experience and the reports of other *in vivo* models and studies.[11, 12, 21] The osteolysis seen at every proximal implant histologically highlights the value of using calves as a model for implant loosening and the suboptimal choice for proximal implant location. Another important limitation of the study is that we were unable to evaluate fracture healing because of the problems that occurred at the beginning of the study with the fracture model.

Because this study was conducted on a small number of neonatal calves, more investigations are necessary to determine the biological behavior of bone around the pin-sleeve system in other species and in older animals. For these situations, varying lengths of sleeves, pins and diameter rings would need to be manufactured. Some in-growth of the bone around the sleeve edges was observed histologically. Since we did not try to remove any sleeves, we are unable to predict how this could affect sleeve removal, but in all likelihood would make it much more challenging. In the papers reporting the adult version of the pin-sleeve system, it was suggested that the sleeve could be left in the bone after cast removal.[40, 51]

Despite the small number of test subjects, convincing evidence was gathered that support the pin-sleeve system's potential use in the clinical setting. For some animals and some fractures, a traditional TP is adequate. However, for young animals with extremely soft bone and for larger or older animals with extremely comminuted fractures where healing times will be prolonged, this novel system provides the possibility to minimize implant loosening, maximize patient comfort and change casts as needed without disrupting the implant-bone interface.

With the knowledge that has been gathered from the laboratory studies and this clinical trial, the PS system is ready for use in the clinic. A multicenter, prospective study evaluating the system's use, limitations, successes and failures will help shape the future of ESF. In the laboratory, future projects to evaluate the PS system should include repeating the notch effect study with the sleeves *in situ*, and the role that metaphyseal bone plays in the solidity of ESF, and how that role changes based on whether it holds the most proximal or most distal implant. Another possible avenue to explore is creating an attachment or sidebars to connect the rings instead of using casting material.

## **Conclusion**

A neonatal calf model was selected because of thin cortices and potentially faster lysis at the bone-implant interface. Via a pilot group of calves, an iatrogenic fracture model was abandoned and more cast padding was placed before cast application. The earlier increase in lameness in calves with TP is attributed to pin loosening and associated pain. Static force-plate measurements appear to be reasonable estimations for cast disease while lameness scores are tied more closely to implant loosening. The metaphyseal-diaphyseal junction where the proximal implants were situated is unsuitable bone for either system, whereas the distal implants were located in more solid, diaphyseal bone. Each proximal implant of both systems and the distal TP implants had minimal bone-implant contact and osteolysis. The PS system results in very little osteolysis when instrumented in diaphyseal bone. The PS could be used as external fixation for comminuted distal limb fracture management, potentially allowing the implants to solidly remain in place long enough for adequate fracture healing.

## Bibliography

1. Tulleners, E.P., *Metacarpal and metatarsal fractures in cattle*. Vet Clin North Am Food Anim Pract, 1996. **12**(1): p. 199-209.
2. Tulleners, E.P., *Metacarpal and metatarsal fractures in dairy cattle: 33 cases (1979-1985)*. J Am Vet Med Assoc, 1986. **189**(4): p. 463-8.
3. Elce, Y.A., et al., *Ex vivo comparison of a novel tapered-sleeve and traditional full-limb transfixation pin cast for distal radial fracture stabilization in the horse*. Vet Comp Orthop Traumatol, 2006. **19**(2): p. 93-7.
4. Ferguson, J.G., *Management and Repair of Bovine Fractures*. The Compendium on continuing education for the practicing veterinarian, 1982. **4**(3): p. S128-S135.
5. Gerstenfeld, L.C., et al., *Application of histomorphometric methods to the study of bone repair*. J Bone Miner Res, 2005. **20**(10): p. 1715-22.
6. Schell, H., et al., *The course of bone healing is influenced by the initial shear fixation stability*. J Orthop Res, 2005. **23**(5): p. 1022-8.
7. Kwong, F.N. and M.B. Harris, *Recent developments in the biology of fracture repair*. J Am Acad Orthop Surg, 2008. **16**(11): p. 619-25.
8. Hirvonen, L.J., et al., *Influence of bone cements on bone-screw interfaces in the third metacarpal and third metatarsal bones of horses*. Am J Vet Res, 2009. **70**(8): p. 964-72.
9. Stadlinger, B., et al., *Surface-conditioned dental implants: an animal study on bone formation*. J Clin Periodontol, 2009. **36**(10): p. 882-91.
10. Niehaus, A.J., et al., *Effects of orthopedic implants with a polycaprolactone polymer coating containing bone morphogenetic protein-2 on osseointegration in bones of sheep*. Am J Vet Res, 2009. **70**(11): p. 1416-25.
11. Anderson, D.E., et al., *Improved osseointegration of calcium phosphate-coated external fixation pins. Studies in calves*. Acta Orthop Scand, 1997. **68**(6): p. 571-6.
12. Aro, H.T., M.D. Markel, and E.Y. Chao, *Cortical bone reactions at the interface of external fixation half-pins under different loading conditions*. J Trauma, 1993. **35**(5): p. 776-85.

13. Francoz, D., et al., *Synovial fluid changes in induced infectious arthritis in calves*. J Vet Intern Med, 2005. **19**(3): p. 336-43.
14. Auer, J.A., et al., *Refining animal models in fracture research: seeking consensus in optimising both animal welfare and scientific validity for appropriate biomedical use*. BMC Musculoskelet Disord, 2007. **8**: p. 72.
15. Bicalho, R.C., et al., *Association between a visual and an automated locomotion score in lactating Holstein cows*. J Dairy Sci, 2007. **90**(7): p. 3294-300.
16. Crawford, W.H. and P.B. Fretz, *Long Bone Fractures in Large Animals: A Retrospective Study*. Vet Surg, 1985. **14**(4): p. 295-302.
17. Anderson, D.E. and G. St Jean, *Management of fractures in field settings*. Vet Clin North Am Food Anim Pract, 2008. **24**(3): p. 567-82, viii.
18. Ames, N.K., *Comparison of methods for femoral fracture repair in young calves*. J Am Vet Med Assoc, 1981. **179**(5): p. 458-9.
19. Marcellin-Little, D.J., *External Skeletal Fixation*, in *Textbook of Small Animal Surgery*, D. Slatter, Editor. 2003, Saunders: Philadelphia. p. 1818-26.
20. Egger, E.L., *Static Strength Evaluation of Six External Skeletal Fixation Configurations*. Vet Surg, 1983. **12**(3): p. 130-136.
21. Sullins, K.E. and C.W. McIlwraith, *Evaluation of 2 types of external skeletal fixation for repair of experimental tibial fractures in foals*. Vet Surg, 1987. **16**(4): p. 255-64.
22. Calhoun, J.H., et al., *Biomechanics of the Ilizarov fixator for fracture fixation*. Clin Orthop Relat Res, 1992(280): p. 15-22.
23. Kummer, F.J., *Biomechanics of the Ilizarov external fixator*. Clin Orthop Relat Res, 1992(280): p. 11-4.
24. Orbay, G.L., V.H. Frankel, and F.J. Kummer, *The effect of wire configuration on the stability of the Ilizarov external fixator*. Clin Orthop Relat Res, 1992(279): p. 299-302.

25. Joyce, J., et al., *Use of transfixation pin casts to treat adult horses with comminuted phalangeal fractures: 20 cases (1993-2003)*. J Am Vet Med Assoc, 2006. **229**(5): p. 725-30.
26. Auer, J.A., *Principles of Fracture Treatment*, in *Equine Surgery*, J.A. Auer and J.A. Stick, Editors. 2006, Saunders: St. Louis. p. 1002-29.
27. Anderson, D.E. and G. St Jean, *External skeletal fixation in ruminants*. Vet Clin North Am Food Anim Pract, 1996. **12**(1): p. 117-52.
28. Lescun, T.B., et al., *Evaluation of transfixation casting for treatment of third metacarpal, third metatarsal, and phalangeal fractures in horses: 37 cases (1994-2004)*. J Am Vet Med Assoc, 2007. **230**(9): p. 1340-9.
29. Kraus, B.M., et al., *Management of comminuted fractures of the proximal phalanx in horses: 64 cases (1983-2001)*. J Am Vet Med Assoc, 2004. **224**(2): p. 254-63.
30. Kaneps, A.J., et al., *Fracture repair with transfixation pins and fiberglass cast in llamas and small ruminants*. J Am Vet Med Assoc, 1989. **195**(9): p. 1257-61.
31. St-Jean, G., M.F. Clem, and R.M. DeBowes, *Transfixation pinning and casting of tibial fractures in calves: five cases (1985-1989)*. J Am Vet Med Assoc, 1991. **198**(1): p. 139-43.
32. Nemeth, F. and W. Back, *The use of the walking cast to repair fractures in horses and ponies*. Equine Vet J, 1991. **23**(1): p. 32-6.
33. Nunamaker, D.M., et al., *A new external skeletal fixation device that allows immediate full weight bearing: application in the horse*. Vet Surg, 1986. **15**(5): p. 345-355.
34. Nunamaker, D.M. and R.A. Nash, *A tapered-sleeve transcortical pin external skeletal fixation device for use in horses: development, application, and experience*. Vet Surg, 2008. **37**(8): p. 725-32.
35. Seltzer, K.L., et al., *The effect of hole diameter on the torsional mechanical properties of the equine third metacarpal bone*. Vet Surg, 1996. **25**(5): p. 371-5.
36. Hopper, S.A., et al., *Effect of pin hole size and number on in vitro bone strength in the equine radius loaded in torsion*. Am J Vet Res, 1998. **59**(2): p. 201-4.

37. Ho, K.W., et al., *The effect of 4 mm bicortical drill hole defect on bone strength in a pig femur model*. Arch Orthop Trauma Surg, 2010. **130**(6): p. 797-802.
38. Moss, D.P. and N.C. Tejwani, *Biomechanics of external fixation: a review of the literature*. Bull NYU Hosp Jt Dis, 2007. **65**(4): p. 294-9.
39. McClure, S.R., J.P. Watkins, and R.B. Ashman, *In vitro comparison of the effect of parallel and divergent transfixation pins on breaking strength of equine third metacarpal bones*. Am J Vet Res, 1994. **55**(9): p. 1327-30.
40. Brianza, S., et al., *Finite element analysis of a novel pin-sleeve system for external fixation of distal limb fractures in horses*. Vet J, 2010.
41. Nunamaker, D.M., et al., *A new external skeletal fixation device that allows immediate full weightbearing* Vet Surg, 1986. **15**(5): p. 345-55.
42. McClure, S.R., B.M. Hillberry, and K.E. Fisher, *In vitro comparison of metaphyseal and diaphyseal placement of centrally threaded, positive-profile transfixation pins in the equine third metacarpal bone*. Am J Vet Res, 2000. **61**(10): p. 1304-8.
43. St-Jean, G. and R.M. Debowes, *Transfixation pinning and casting of radial-ulnar fractures in calves: A review of three cases*. Can Vet J, 1992. **33**(4): p. 257-262.
44. Matthews, L.S., C.A. Green, and S.A. Goldstein, *The thermal effects of skeletal fixation-pin insertion in bone*. J Bone Joint Surg Am, 1984. **66**(7): p. 1077-83.
45. Swaim, S.F., et al., *Evaluation of the dermal effects of cast padding in coaptation casts on dogs*. Am J Vet Res, 1992. **53**(7): p. 1266-72.
46. Behrens, F., *General theory and principles of external fixation*. Clin Orthop Relat Res, 1989(241): p. 15-23.
47. Moroni, A., et al., *State of the art review: techniques to avoid pin loosening and infection in external fixation*. J Orthop Trauma, 2002. **16**(3): p. 189-95.
48. Checketts, R.G. and M. Otterburn, *Pin tract infection: definition, prevention, incidence.*, in *2nd Riva Congress*. 1992: Riva di Garda, Italy. p. 98-99.
49. Green, S.A., *Complications of external skeletal fixation*. Clin Orthop Relat Res, 1983(180): p. 109-16.

50. Nash, R.A., D.M. Nunamaker, and R. Boston, *Evaluation of a tapered-sleeve transcortical pin to reduce stress at the bone-pin interface in metacarpal bones obtained from horses*. Am J Vet Res, 2001. **62**(6): p. 955-60.
51. Brianza, S., et al., *In vitro mechanical evaluation of a novel pin-sleeve system for external fixation of distal limb fractures in horses: a proof of concept study*. Vet Surg, 2010. **39**(5): p. 601-8.
52. Huiskes, R., E.Y. Chao, and T.E. Crippen, *Parametric analyses of pin-bone stresses in external fracture fixation devices*. J Orthop Res, 1985. **3**(3): p. 341-9.
53. Singh, G.R., et al., *Evaluation of two dynamic axial fixators for large ruminants*. Vet Surg, 2007. **36**(1): p. 88-97.
54. Anderson, D. and F. Silveira, *Effect of pin size and pin tract osteolysis on removal torque of positively threaded transfixation pins used in external skeletal fixation in cattle: a prospective study*, in *World Buiatrics Congress*. 2010: Santiago, Chile.
55. Saithna, A., *The influence of hydroxyapatite coating of external fixator pins on pin loosening and pin track infection: a systematic review*. Injury, 2010. **41**(2): p. 128-32.
56. Hamilton, G.F. and E.P. Tulleners, *Transfixation pinning of proximal tibial fractures in calves*. J Am Vet Med Assoc, 1980. **176**(8): p. 725-7.
57. Katz, J.L., et al., *Multiscale mechanics of hierarchical structure/property relationships in calcified tissues and tissue/material interfaces*. Mater Sci Eng A Struct Mater, 2007. **27**(3): p. 450-468.
58. Schneider, R.K., et al., *Effect of three types of half-limb casts on in vitro bone strain recorded from the third metacarpal bone and proximal phalanx in equine cadaver limbs*. Am J Vet Res, 1998. **59**(9): p. 1188-93.
59. Marson, B.M. and M.A. Keenan, *Skin surface pressures under short leg casts*. J Orthop Trauma, 1993. **7**(3): p. 275-8.
60. Brianza, S., et al., *Comparative notch effect evaluation for the removal of two different implants for distal limb fracture in large animals*. Vet Surg, 2011. **Submitted**.



61. Brianza, S., et al., *Ex vivo evaluation of the pin-sleeve system*. Vet Surg, 2011. **Under revisions**.
62. Young, B. and J. Heath, *Skeletal Tissues*, in *Wheaters Functional Histology*, B. Young and J. Heath, Editors. 2002, Churchill Livingstone: Edinburgh. p. 175-88.
63. Blikslager, A.T., et al., *Holding power of orthopedic screws in the large metacarpal and metatarsal bones of calves*. Am J Vet Res, 1994. **55**(3): p. 415-8.
64. Trostle, S.S., et al., *In vitro biomechanical comparison of solid and tubular interlocking nails in neonatal bovine femurs*. Vet Surg, 1995. **24**(3): p. 235-43.
65. Martin, R.B. and J. Ishida, *The relative effects of collagen fiber orientation, porosity, density, and mineralization on bone strength*. J Biomech, 1989. **22**(5): p. 419-26.
66. Peterlik, H., et al., *From brittle to ductile fracture of bone*. Nat Mater, 2006. **5**(1): p. 52-5.
67. McClure, S.R., et al., *In vitro comparison of the standard short limb cast and three configurations of short limb transfixation casts in equine forelimbs*. Am J Vet Res, 1994. **55**(9): p. 1331-4.
68. Singh, G.R., et al., *In vitro biomechanical properties of linear, circular, and hybrid external skeletal fixation devices for use in large ruminants*. Vet Surg, 2007. **36**(1): p. 80-7.
69. Zacharias, J.R., et al., *Comparison of insertion characteristics of two types of hydroxyapatite-coated and uncoated positive profile transfixation pins in the third metacarpal bone of horses*. Am J Vet Res, 2007. **68**(11): p. 1160-6.
70. McClure, S.R., J.P. Watkins, and H.A. Hogan, *In vitro evaluation of four methods of attaching transfixation pins into a fiberglass cast for use in horses*. Am J Vet Res, 1996. **57**(7): p. 1098-101.
71. Morisset, S., et al., *In vitro comparison of the use of two large-animal, centrally threaded, positive-profile transfixation pin designs in the equine third metacarpal bone*. Am J Vet Res, 2000. **61**(10): p. 1298-303.

72. Hopper, S.A., et al., *In vitro comparison of transfixation and standard full-limb casts for prevention of displacement of a mid-diaphyseal third metacarpal osteotomy site in horses*. Am J Vet Res, 2000. **61**(12): p. 1633-5.
73. Seebeck, P., et al., *Gait evaluation: a tool to monitor bone healing?* Clin Biomech (Bristol, Avon), 2005. **20**(9): p. 883-91.
74. Garfin, S.R., et al., *Quantification of intracompartmental pressure and volume under plaster casts*. J Bone Joint Surg Am, 1981. **63**(3): p. 449-53.
75. Uslu, M.M. and A. Apan, *Can skin surface pressure under a cast reveal intracompartmental pressure?* Arch Orthop Trauma Surg, 2000. **120**(5-6): p. 319-22.
76. Estebe, J.P., et al., *Motor blockade by brachial plexus block in the sheep*. Anesthesiology, 2000. **93**(1): p. 291-3.
77. Poupeau, D., *Mis au point d'une technique d'anesthésie du plexus brachial chez le veau*, in *Clinical Sciences*. 2009, Université de Montréal: St-Hyacinthe. p. 78.

## **Appendix A: Pilot Study, 6 calves**

**Materials and methods:** Following the surgical procedure listed in the article, the right front forelimbs of six calves were implanted with either transcortical pins (n=3) or pin-sleeves (n=3). A 30° oblique osteotomy was made to recreate a clinical situation of an unstable fracture. The fracture was created by circumferentially elevating the periosteum after a lateral incision was made over the distal diaphysis. An oscillating saw created the osteotomy under constant saline irrigation. Minimal bleeding was observed from the osteotomy site. The periosteum was not sutured and the skin was closed with USP 0 polydioxanone suture in a cruciate pattern. The limbs were subsequently padded with a double layer stockinette and casted as previously described.

**Results:** Five of the six calves had severe cast disease noted at euthanasia/cast removal. Erosions were noted on the dorsal surfaces of the medial and lateral metacarpophalangeal and proximal interphalangeal joints. One calf had extensive bruising around the coronary band of the casted limb and its hooves fell off during gentle digital manipulation to expose a completely bruised corium.

Below are examples of the osteotomized limbs of the pilot study calves at surgery and at euthanasia.

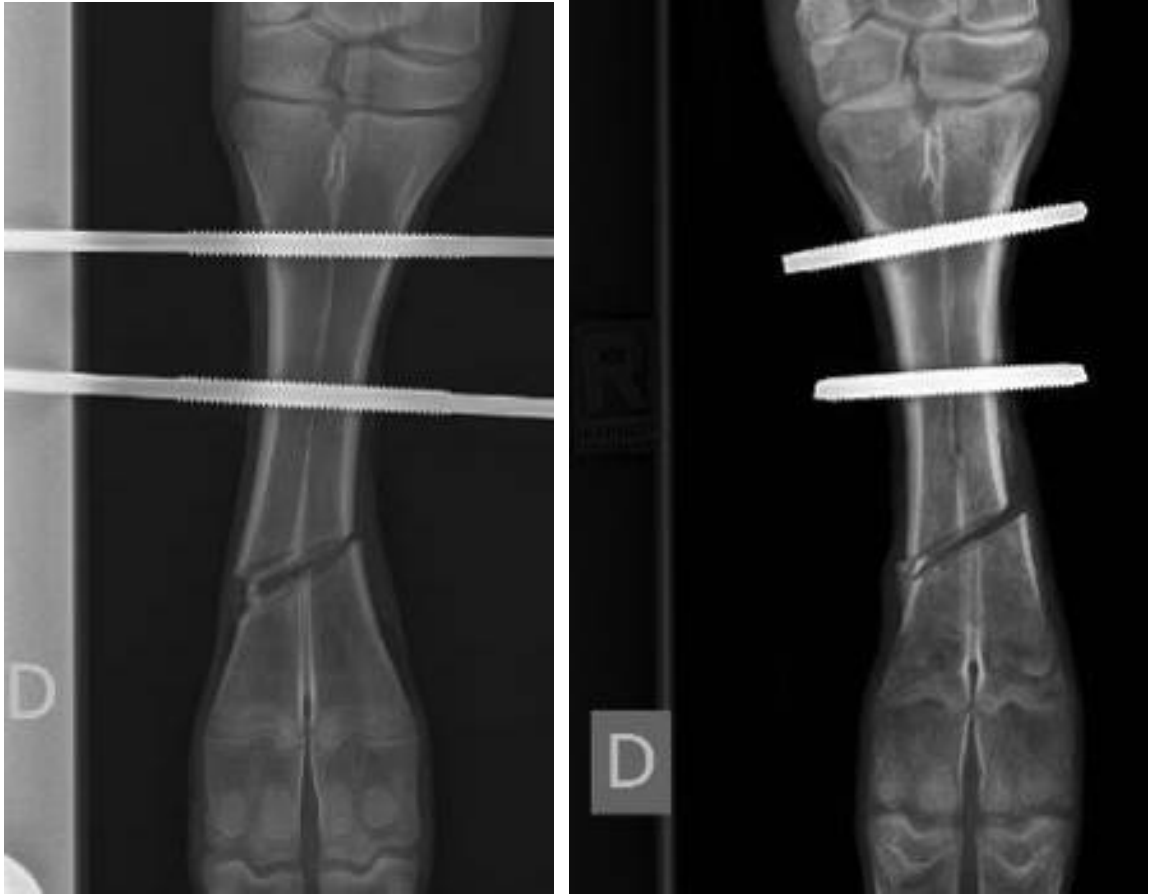

Figure 14. Pilot study radiographs of TP calf. Dorso-palmar radiographs of a TP calf at surgery (left) and at euthanasia (right). There is no visible callous formation at the osteotomy.

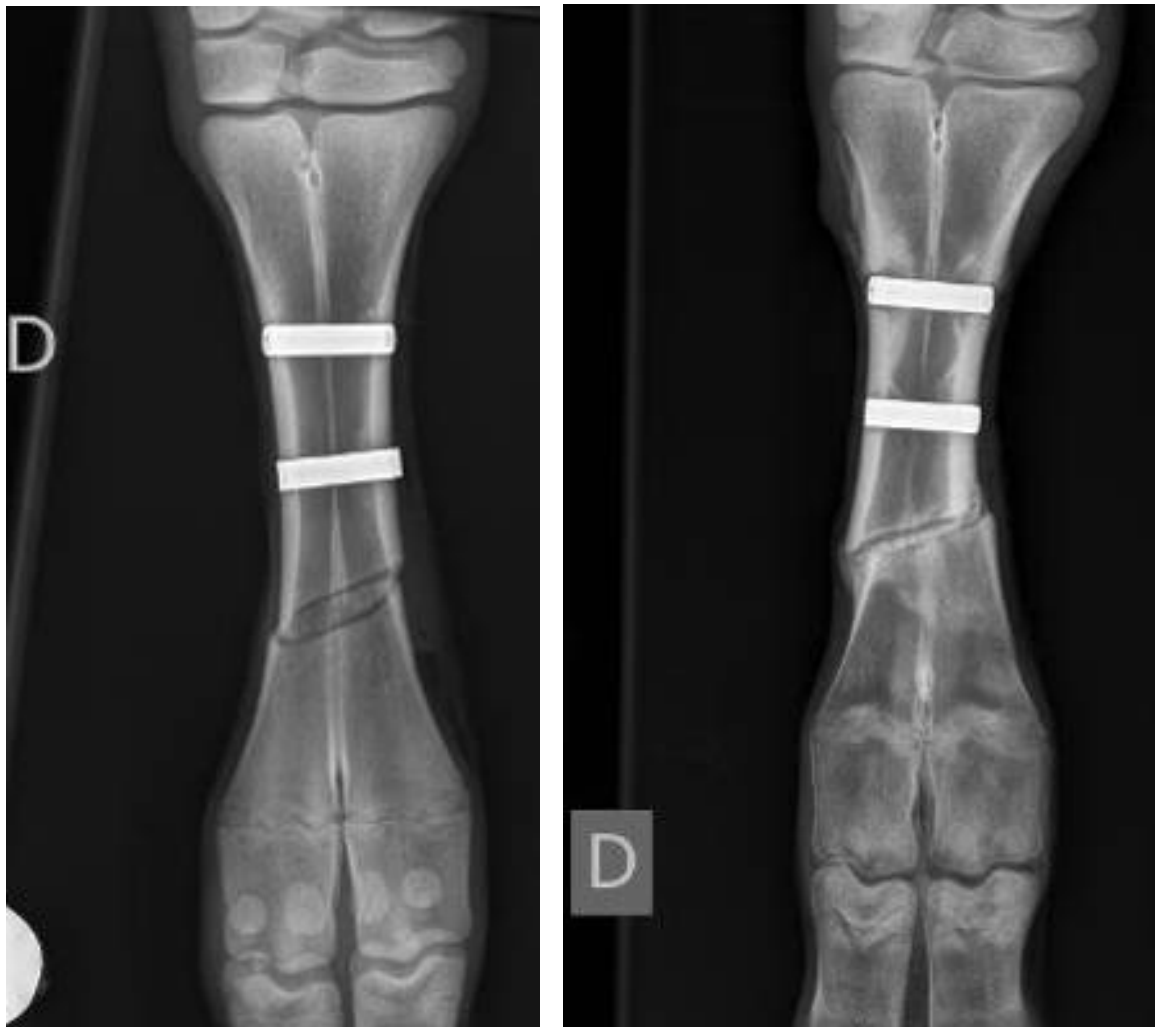


Figure 15. Pilot study radiographs of PS calf. Dorso-palmar radiographs of a PS calf from surgery (left) and at euthanasia (right). Callous formation is evident after 28 days.

## Appendix B: Static force plate

**Materials and Methods:** On a flat, even surface, 4 commercial shipping balances (max capacity 65 kg, accuracy  $\pm 0.1$ kg) with read-out lectures were seated in the corners of a custom-made wood frame so that they were spaced to accommodate one limb per scale. Each balance was used for the same limb for every session, and the read-out lectures were fixed to a board in the same order. Velcro was attached to the scales and the underside of a carpet so that the surface would appear flat, even and non-threatening to the calves. The outline of each scale and corresponding limb was marked on the carpeting. Sheets were hung on the front and sides of the calves to minimize environmental distraction. A nipple from a calf bottle was fixed to the center of a board in front of the calf, which was secured at the height of the calves' muzzle. A camera attached to a tripod was focused on the scale read-outs was pre-programmed to take 10 consecutive photos with no flash and no delay of the weight placed by each of the calves' limbs. Read-out weights where each calf had one limb on each scale were recorded until 10 data points were acquired, and this was performed three times per week. If the calf moved, lifted up its leg, or stepped off of the scale, the limbs were replaced and more data was collected. After each data collection, the photos were transferred to a computer and the first 10 values of unadulterated weight-bearing on all 4 limbs for each calf were entered into a spreadsheet where the percentage of weight placed on each limb was calculated.

The same investigator (SRV) always performed the setup, data collection and data entry so as to eliminate errors and variability. Calves were transported to and from the static force plate while standing on a small chariot in order to respect the exercise restriction placed on them by study protocol.

**Results:** Before surgery, all calves placed nearly equal amount of weight on the left and right front limbs (value near 0.5). Over time all calves unloaded their right limb and overloaded their left limb. At then end of the study, TP calves and PS calves had almost equal values. Below is a table and chart representing the front limb data from all sixteen

calves. The pilot group calves unloaded their limbs to a greater degree than the study calves.

<b>Days</b>	<b>Pincast Pilot</b>	<b>Pincast</b>	<b>Pinsleeve pilot</b>	<b>Pinsleeve</b>
<b>0</b>	0.47 ±0.02	0.51 ±0.07	0.51 ±0.03	0.48 ±0.06
<b>3</b>	0.81 ±0.09	0.56 ±0.12	0.69 ±0.08	0.61 ±0.12
<b>6</b>	0.75 ±0.19	0.51 ±0.11	0.71 ±0.07	0.59 ±0.11
<b>8</b>	0.74 ±0.19	0.59 ±0.12	0.72 ±0.08	0.55 ±0.16
<b>10</b>	0.74 ±0.21	0.64 ±0.26	0.84 ±0.05	0.59 ±0.13
<b>13</b>	0.70 ±0.23	0.64 ±0.23	0.86 ±0.04	0.62 ±0.09
<b>15</b>	0.73 ±0.21	0.74 ±0.15	0.88 ±0.06	0.69 ±0.13
<b>17</b>	0.85 ±0.23	0.69 ±0.08	0.89 ±0.07	0.66 ±0.11
<b>20</b>	0.91 ±0.12	0.55 ±0.12	0.92 ±0.07	0.59 ±0.18
<b>22</b>	0.96 ±0.03	0.73 ±0.12	0.93 ±0.04	0.72 ±0.21
<b>24</b>	0.79 ±0.25	0.72 ±0.14	0.92 ±0.07	0.61 ±0.22
<b>27</b>	0.98	0.82 ±0.17	0.96 ±0.04	0.78 ±0.13

Table IV: Static force plate data. All data listed are the mean ± standard deviation. A ratio was calculated of left front weight to right front weight. The right front limb of each animal was the operated limb. Increasing numbers indicate unloading of the right, operated limb and increased loading of the left front limb. Day 0 measurements were taken before surgery and all other days are numbered counting surgery as day 1.

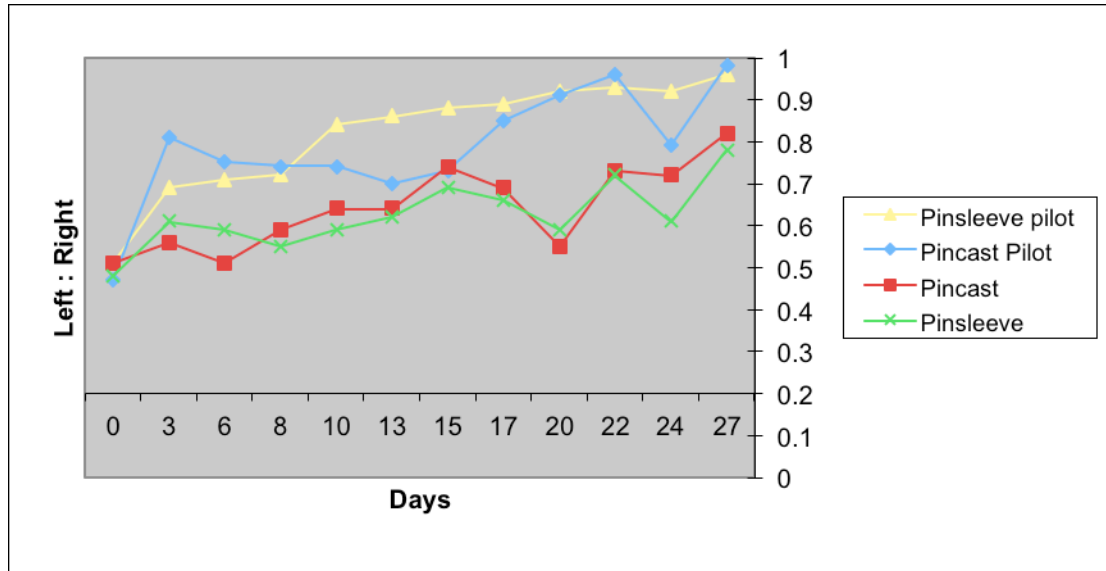


Figure 16. Static force plate graphic. Illustration of the ratio of body weight placed on the left vs. the right (operated) forelimb. Increasing values indicate more weight on the left limb and unloading of the right limb.



## Appendix C: Surgical instruments and technique

The following are photos and descriptions of the surgical instruments and techniques used to complete this study.

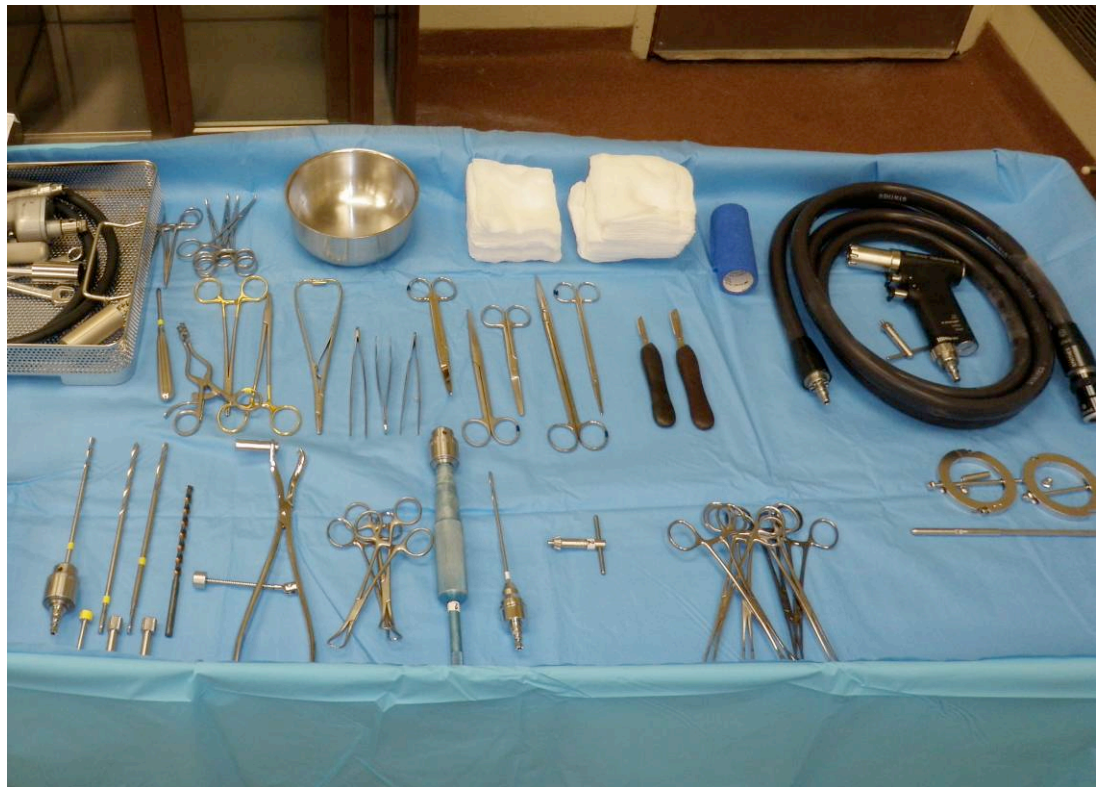

Figure 17. Surgery table for a PS surgery. Drill guides, drill sleeves, drill bits, assembled pin-sleeve systems.

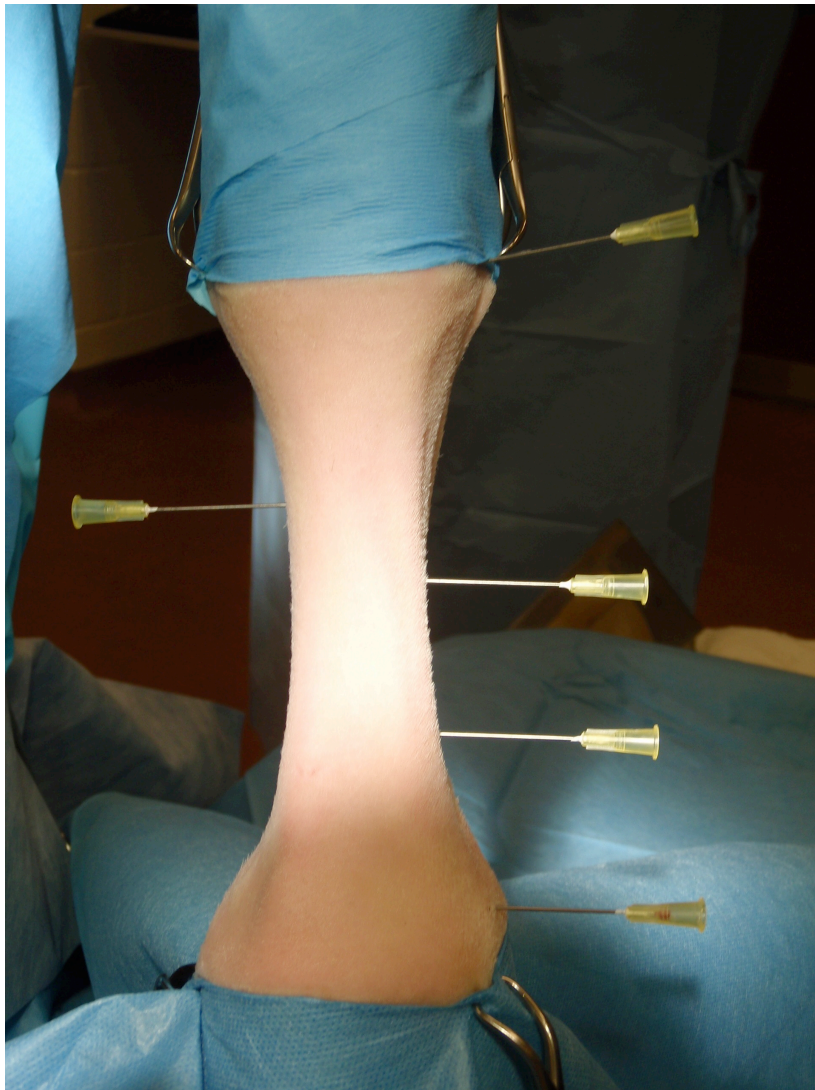


Figure 18. Needle placement. The calf is in dorsal recumbency with the right limb suspended and the dorsal aspect of the metacarpus can be seen. Needles are placed from top to bottom in the physis, distal diaphysis, mid diaphysis, diaphyseal-metaphyseal junction and carpo-metacarpal joint.

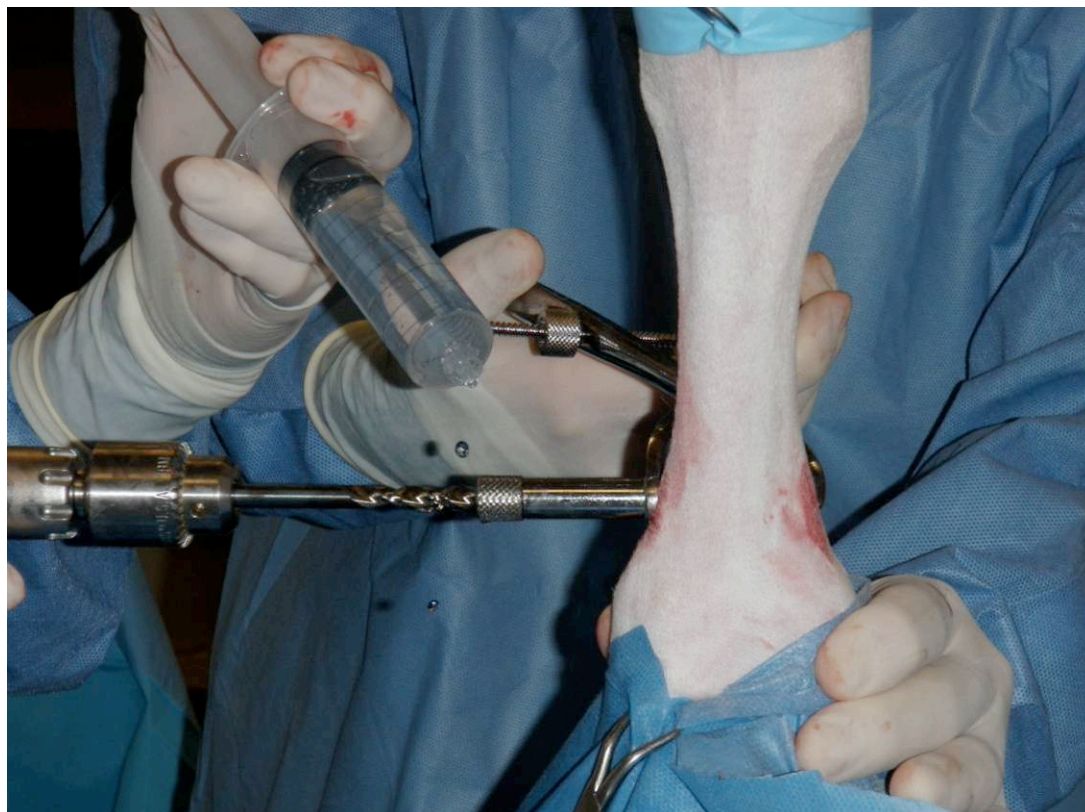

Figure 19. Drill guide with sleeve. The drill sleeve is inserted into the clamp and 6.4 mm drill bit is drilled into the proximal metacarpus with the calf in dorsal recumbency. The dorsal surface of the right metacarpus is visible. Sterile saline in the syringe was used to irrigate and lubricate during drilling.

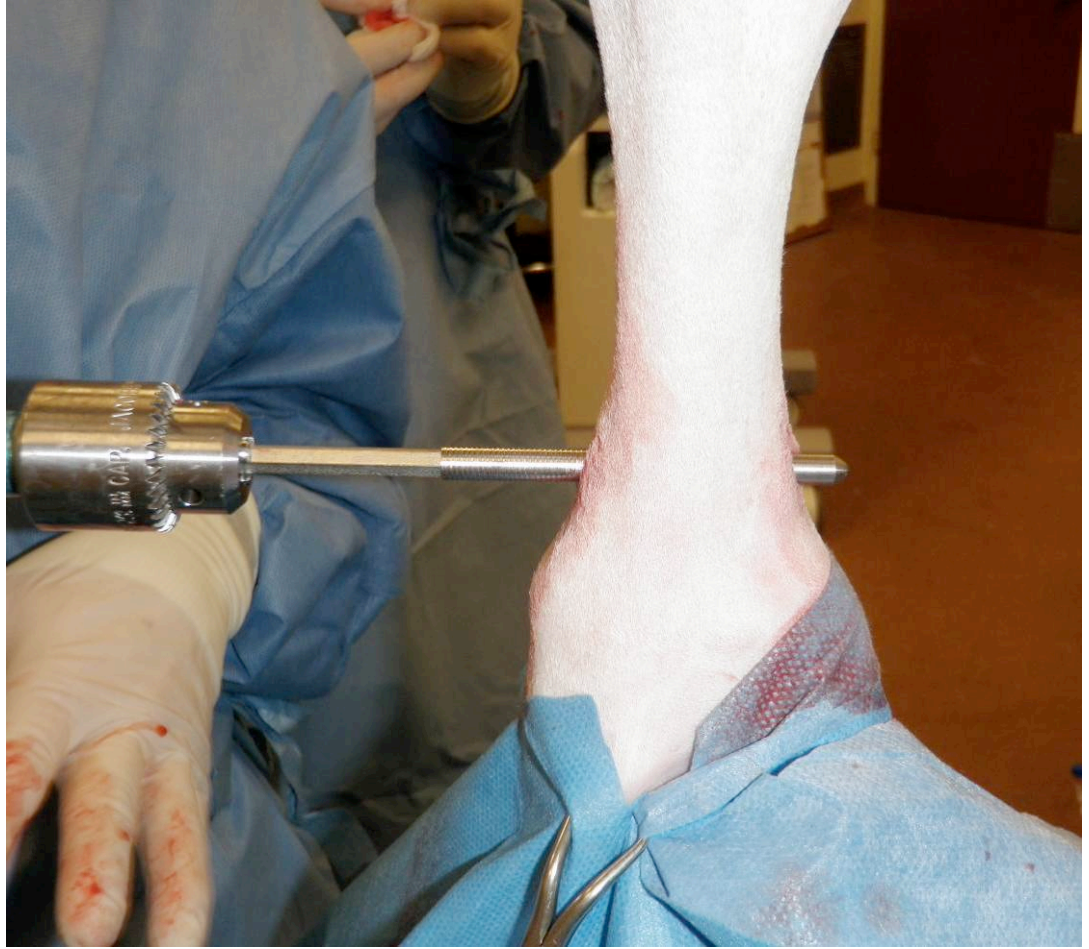

Figure 20. Hand insertion of the sleeve. The calf is in dorsal recumbency and the dorsal surface of the right metacarpus is visible. The custom-made insertion instrument allows the sleeve to be screwed into the bone and the disassembled leaving the sleeve in the bone.

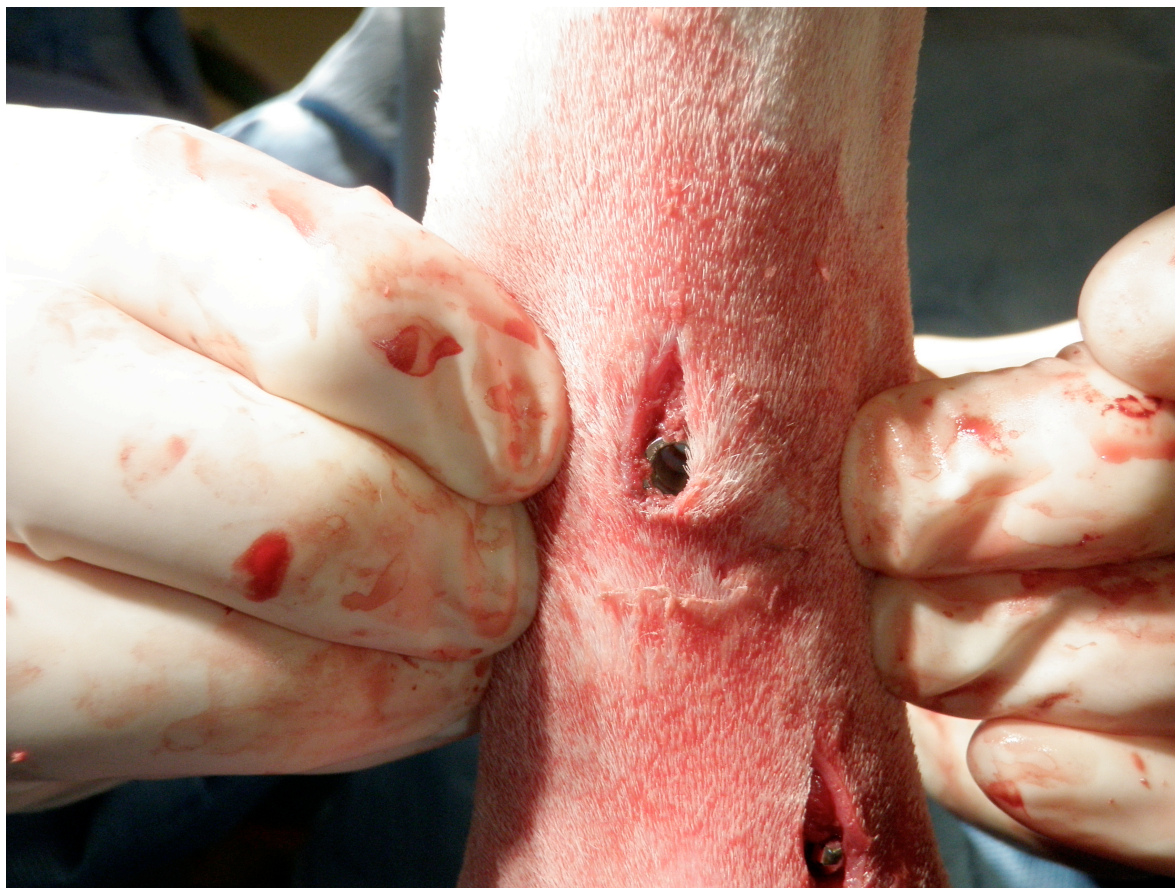

Figure 21. Inserted sleeve. After hand insertion, the sleeve was dismounted from the insertion device. A small length of the sleeve can be seen extending past the cortex and periosteum in this photo.

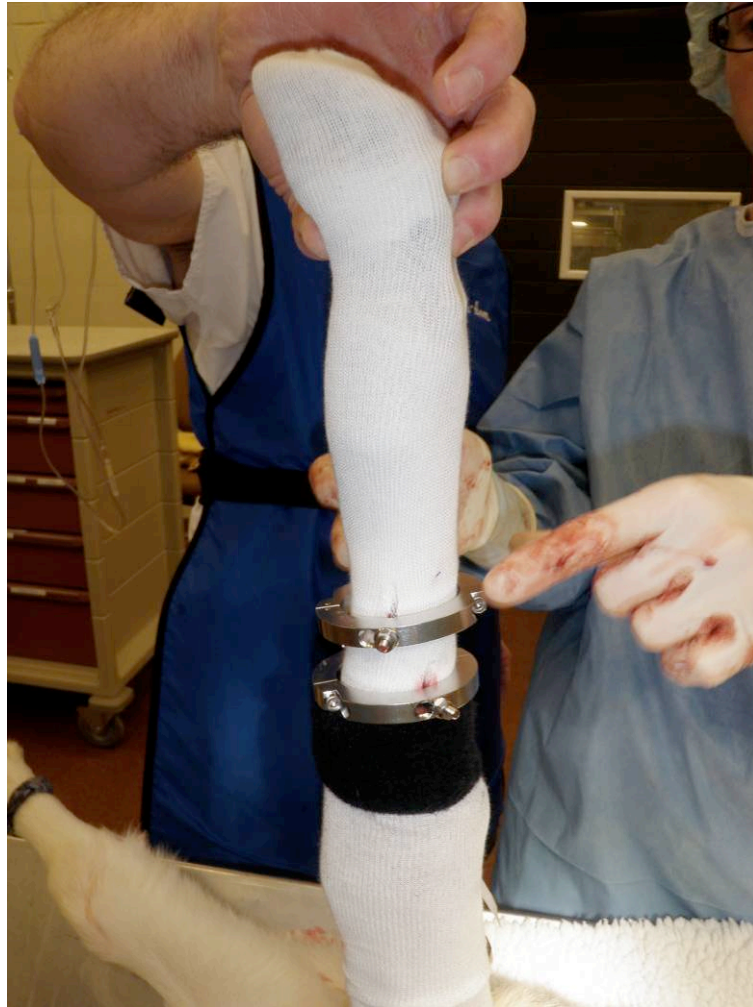

Figure 22. PS ring assembly in a pilot calf. The calf is in dorsal recumbency. Stockinette covers the distal limb. The rings have been bolted together around the limb and secured to the pins. Felt padding has been wrapped around the leg proximal to the proximal ring.

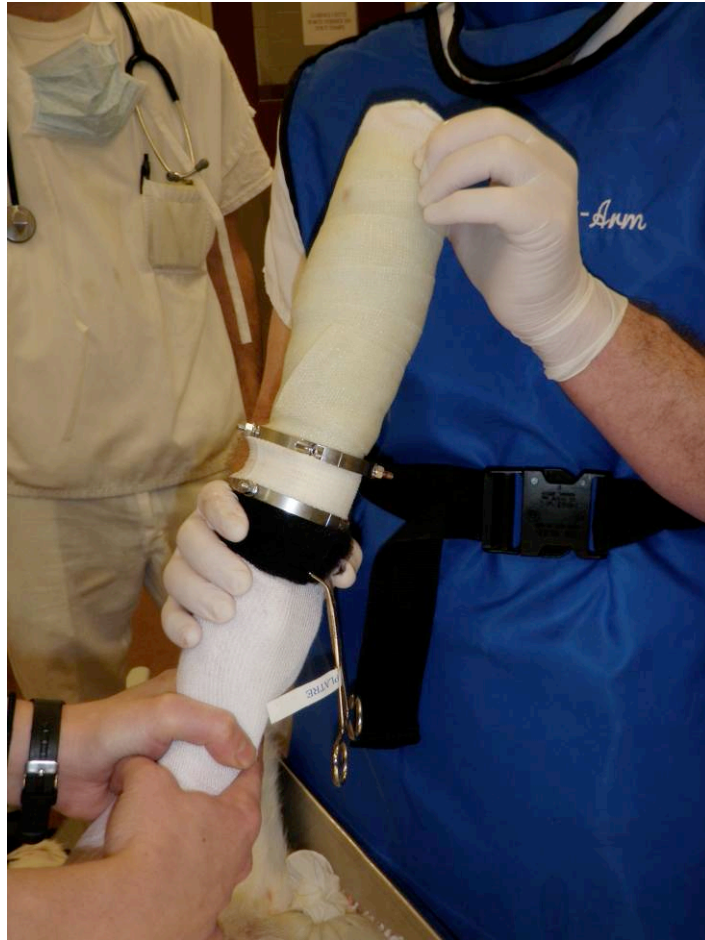

Figure 23. Cast application for PS pilot calf. One inch casting material has been wrapped around the limb, between the rings. Three inch casting material has been wrapped around the limb distal to the distal ring, including the hooves. The final layer of cast material will incorporate the rings into the cast while leaving the nuts exposed to ensure they remained adequately tightened. The proximal felt padding is visible and held in place with a towel clamp.

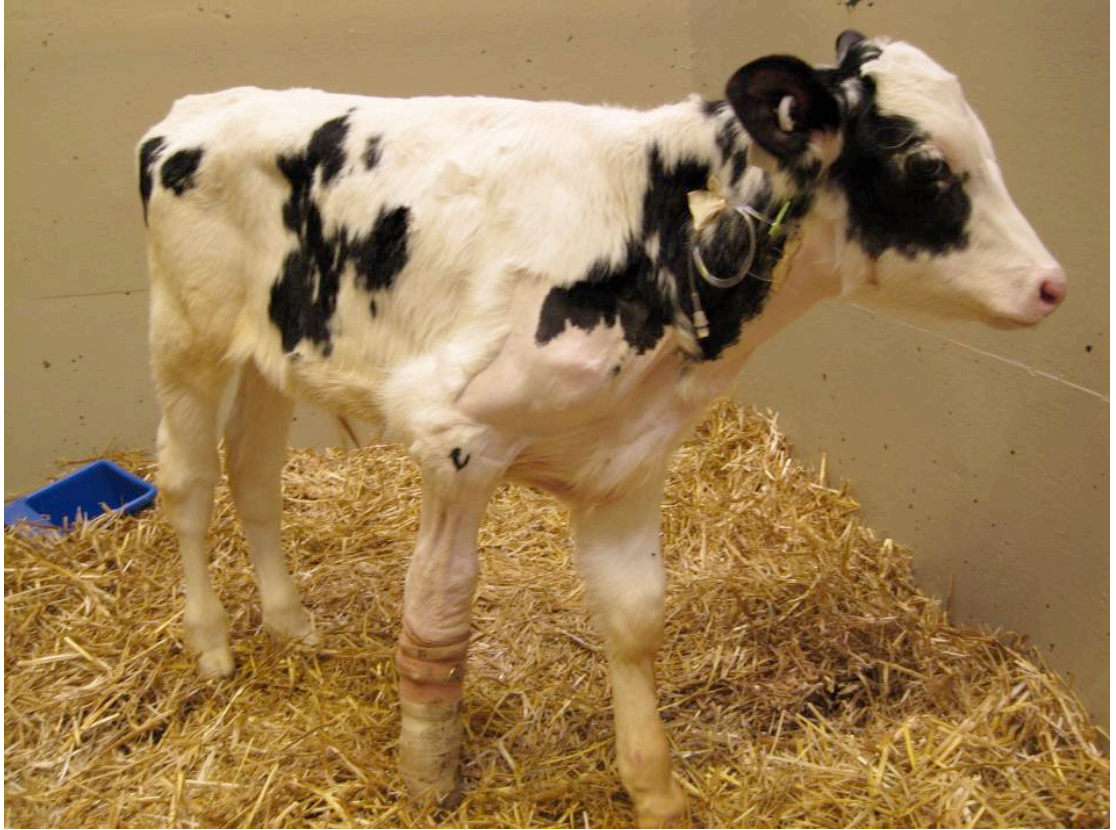

Figure 24. PS calf 4 hours post-op. The shaved area over the shoulder from the brachial plexus block is visible. The calf appears alert and weight bearing on both front limbs. A catheter is in the right jugular vein.