

1 **Identification of a novel herpesvirus associated with cutaneous ulcers**
2 **in a fisher (*Martes pennanti*)**

3
4
5 Carl A. Gagnon,¹ Josée Tremblay, Danielle Larochelle, Nedzad Music, Donald Tremblay

6
7 From the Diagnostic Services Section (Gagnon, Music, Tremblay), the Swine Infectious
8 Disease Research Centre (Gagnon), and the Research Group on Infectious Diseases of Swine
9 (Gagnon); Faculty of Veterinary Medicine, University of Montreal, St-Hyacinthe; from the St-
10 Felicien Wildlife Zoo (Tremblay), St-Felicien; and from the Animal Pathology Expertise
11 Laboratory (Larochelle), Quebec's Ministry of Agriculture Fisheries and Food, Quebec, Canada.

12
13 ¹**Corresponding author:** Dr Carl A. Gagnon, Faculty of Veterinary Medicine, University
14 of Montreal, 3200 Sicotte Street, St-Hyacinthe, Quebec, Canada, J2S 7C6. Phone: 450-773-8521
15 (extension 8681). Fax: 450-778-8113. carl.a.gagnon@umontreal.ca

1
2
3
4
5
6
7
8
9
10
11
12
13
14
15
16

Abstract. On December 8th, 2008, a male fisher (*Martes pennanti*) housed in a quarantine enclosure at the St-Félicien Zoo was found dead with multiple skin ulcers on the muzzle and plantar pads. At necropsy, no major findings were found, and a specific cause of death was not determined microscopically. However, at the borders of ulcerated sites, there were increased numbers of koilocytes, with perinuclear vacuolation and nuclear enlargement. A pan-herpesvirus nested-polymerase chain reaction (PCR) assay was conducted, and an expected PCR product of 230 nucleotides was obtained within tissues collected from around the skin ulcers. Other tissues, including intestines and pool of lung, liver and kidney, tested negative. The obtained PCR amplicon was sequenced and was highly related to the partial viral DNA polymerase (DPOL) gene of a *Badger herpesvirus*. Virus isolation was negative, and no virion was detected by electron microscopy. The pathogenic potential of this novel herpesvirus and its role in the death of the fisher are unknown.

Key words: fisher, FiHV, herpesvirus, *Martes pennanti*, skin, ulcer.

1 The fisher (*Martes pennanti*) is a fur animal of the size of a domestic cat with a long tail
2 and short legs, classified in the *Mustelidae* family.¹⁵ As a generalist predator, the fisher's diet
3 consists predominantly of North American porcupines, snowshoe hares, squirrels, small
4 mammals, birds, carrion, and, to a lesser extent, fruits and plants.^{10,11} Fishers have been reported
5 in the forest regions of several states of the United States of America (USA) and provinces of
6 Canada.^{11,14}

7 On October 2nd 2008, two couples of captive born fishers, each aged 2 ½-years, were
8 bought from a breeding farm in Minnesota, USA, and sent to the St-Félicien Zoo, Quebec,
9 Canada. While in quarantine, a physical exam was performed under anesthesia 6 days after their
10 arrival. Hematology and biochemistry blood tests were normal except for a marginal uremia of
11 16.9 mmol/L [reference values: 3.57-12.14 mmol/L] detected in one of the males. Fecal and
12 radiographic exams were performed and no significant clinical findings were recognized.

13 On December 8th 2008, the male fisher that was previously found marginally uremic on
14 October 2008, was found dead in its quarantine enclosure with multiple skin ulcers on the
15 muzzle and plantar pads (Fig. 1). A variety of causes could induced ulcerative skin lesions but
16 with the gross lesions of the muzzle and plantar pads, *Feline calicivirus* (FCV), and *Feline*
17 *herpesvirus* (FHV), *Canine distemper virus* (CDV) as well as frostbite were considered as
18 possible causes. The three other healthy fishers had shown no clinical signs of illness.

19 On gross examination, the fisher, which had lost 3.7 pounds in body weight, had no fat in
20 the body cavities or surrounding the organs. There were patchy losses of hair on both sides of the
21 flanks and on the hips. The most remarkable lesions were the sharply demarcated and deep,
22 round to oval ulcerations of approximately 0.5 to 1.0 cm in size located on all paws and footpads,
23 and on the muzzle (Fig. 1). Selected few grams of tissues (brain, lung, heart, liver, kidney, lymph

1 nodes, spleen, stomach, bladder, intestine, pancreas, adrenals, thyroids, muscles and skin) were
2 taken for light microscopic evaluation examination, toxicology,^a bacteriology,^b
3 immunohistochemistry,^c electron microscopy examination,^c virus isolation, and for polymerase
4 chain reaction (PCR) assays.

5 A specific cause of death was not determined microscopically. Noteworthy, endocrine
6 dermatosis might be considered to explain the marginal alopecia. Thus, sections of the skin with
7 alopecia, adrenal and thyroid glands were examined. Thickness of the epidermis varied from 4-5
8 cells thick, which might be normal, to 1-2 cells thick, suggestive of epidermal atrophy. In these
9 regions, the hair follicles appeared atrophied. No cortical hyperplasia or hypoplasia, neither
10 nodular hyperplasia were noticed in the adrenal glands. No remarkable changes were noted in the
11 thyroid. No specific tests were done to assess the hormonal status of the animal. Beneath the
12 ulcers noted grossly, there were occasional fibrin thrombi and mild superficial infiltrate of
13 neutrophils, lymphocytes and plasmacytes (data not shown). At the margin of the ulcerated sites,
14 the epidermis is thickened with increased numbers of koilocytes, with perinuclear vacuolation
15 (Fig. 2b) and nuclear hypertrophy. Occasionally, there were scattered discrete cytoplasmic
16 basophilic and, rarely, eosinophilic (not shown) inclusion-like material within the vacuoles (Fig.
17 2c) and areas with large, pale amphophilic intranuclear inclusions, which displaced the
18 chromatin peripherally (Figs. 2c and 2d). No intralesional bacteria were detected following Gram
19 and Periodic acid-Schiff stains.

20

21 A heavy metals screen panel (selenium, copper, arsenic, lead, iron and zinc) performed in
22 the liver was negative. Lung, liver and colon were sent for aerobic culture on blood agar plate
23 (containing 5% (v/v) defibrinated sheep's blood) with overnight incubation at 37^oC. No

1 pathogenic bacteria were found. Using an avidin-biotin complex immunoperoxidase method, the
2 following antibodies were used to detect viral antigens: 1) rabbit anti-measles virus,^d which
3 detects antigen from several viruses classified within the *morbillivirus* species, including CDV;
4 2) rabbit anti-*adenovirus type 2*,^e which detects antigen from a number of *mastadenovirus*
5 species, including *Canine, Bovine and Equine adenovirus*; and 3) monoclonal antibodies specific
6 for FHV (clone FHV7-7)^c and FCV (clone FVCS-19).^c Consistency of staining for each antigen
7 was confirmed using tissue sections from known positive cases stained in parallel with the fisher
8 tissues. Immunostaining for CDV in the skin and brain and for FHV, FCV, and adenovirus in the
9 skin were negative.

10

11 Virus isolation was attempted using Madin-Darby canine kidney (MDCK) and Crandell
12 feline kidney (CRFK) cell lines^f because they are well known to permit the isolation of several
13 types of viruses.^{2,4,7,8} The fetal mink lung epithelial cell line (ML)^g was also used because it is
14 derived from a member of the *Mustelidae* family.¹ Ten days old embryonated eggs^h (inoculated
15 into the chorioallantoic sac and the chorioallantoic membrane) were also used for virus isolation.
16 Unfortunately, all virus isolation attempts were negative. Skin lesions and surrounding tissues
17 were ground in a glass tissue homogenizer and then prepared accordingly (as cell culture
18 supernatants and allantoic fluids) and thereafter negatively stained for electron microscopy
19 visualization. No virus particle could be observed in any of the prepared samples.

20 A pan-herpesvirus nested-PCR assay was conducted as previously described.^{3,13} Briefly,
21 DNA was extracted from 1g of tissue sample, including skin, intestines and a pool of lung, liver
22 and kidney, with the QIAamp DNA mini kitⁱ according to the manufacturer's tissue protocol.
23 The PCR was carried out with the QIAGEN Fast Cycling PCR kit,ⁱ according to the

1 manufacturer's specifications, with a set of three primers (DFA, ILK and KG1) as previously
2 described.¹³ Nested-PCR was then performed under the same conditions using 5 µL of the first
3 PCR reaction and two other primers (TGV, IYG), as previously described.¹³ An expected PCR
4 product of 230 nucleotides (nt) was obtained only with skin tissues collected from and around
5 the ulcers. The obtained PCR products were sequenced using a standard automated sequencing
6 method^j and a sequence of 219 nt in length was submitted to GenBank Basic Local Alignment
7 Search Tool (BLAST) for comparison. The BioEdit Sequence Alignment Editor software with
8 the CLUSTAL W alignment method^k was used for nt and amino acids (aa) comparisons.
9 Nucleotide comparison showed that the nearest nt homology was with the viral DNA polymerase
10 (DPOL) gene of *Badger herpesvirus* (BadHV), which is a virus classified in the *Herpesviridae*
11 family within the subfamily *Gammaherpesvirinae*.¹ The *Fisher herpesvirus* (FiHV) partial
12 sequence possesses 85.3% nt identity and 91.7% aa identity with the BadHV DPOL gene
13 published sequence (Fig. 3). Compared to BadHV, FiHV possesses a total of 23 nt silent
14 mutations over a total of 32 nt mutations (Fig. 3). From a total of 73 deduced aa, 67 aa are
15 identical between FiHV and BadHV (Fig. 3). Attempts to increase the length and the yield of the
16 PCR product obtained by the pan-herpesvirus nested-PCR assay, and to amplify other viral
17 genomic regions of the FiHV by designing new PCR primers based on the reported sequences of
18 BadHV were unsuccessful.

19 Frostbite could cause vascular changes followed by epidermal necrosis but will most
20 often affect the extremities like tips of the ears and tail. The footpads lesions were particularly
21 similar to the cutaneous lesions observed when cats are infected with a systemic virulent strain of
22 FCV⁹ but immunohistochemistry results were negative for FCV. CDV is known to infect animals
23 classified within *Mustelidae* and to induce typical hyperkeratosis skin lesions located at the same

1 sites where the fisher's ulcerative lesions were observed. Noteworthy, all CDV diagnostic results
2 were negative and no microscopic lesions associated with CDV infection was found in tissues.
3 Herpesviruses are well known to cause ulcers of the skin and mucosa to several mammals.⁶ It is
4 possible that FiHV could be involved in the formation of the skin ulcers, but many animals are
5 known to harbor herpesviruses asymptotically.⁶ Unfortunately, no virus was isolated and
6 observed by EM. If FiHV was the etiological cause of the lesions, it would be expected to
7 observe virions by EM within and surrounding the cutaneous ulcers lesions. Noteworthy, the EM
8 technical approach that was used possesses low sensitivity. In spite of the fact that the
9 macroscopic skin lesions were impressive, the histopathological findings were rather mild and
10 not typical of classic herpesvirus diseases (Fig. 2). It is noteworthy that similar histopathological
11 findings have been previously observed in cases of herpesvirus associated skin lesions reported
12 in cats and green sea turtles.^{5,12} Thus, the detection of FiHV DNA only within skin lesions and
13 not in other tissues as well as the absence of other known pathogens in those lesions suggests
14 that FiHV might be associated with the formation of such ulcers, but these findings alone are
15 certainly not conclusive.

16 Is it possible that the pan-herpesvirus nested-PCR assay gave a false positive result? It is
17 believed that if it was the case, then there is a good chance that this PCR assay would be positive
18 for other fisher tissues, which was not the case (data not shown). The novel viral DNA sequence
19 of FiHV was most closely related to the badger herpesvirus, a member of the subfamily
20 *Gammaherpesvirinae*.¹ Like the fisher, the badger is an animal classified in the *Mustelidae*
21 family.¹⁵ Thus, it is reasonable to assume that FiHV is a new herpesvirus classified in the
22 subfamily *Gammaherpesvirinae*. Further fisher cases would have to be studied and additional

1 work is needed to establish the involvement of FiHV in the ulcer lesions and in the death of the
2 animal.

3

4

Acknowledgements

5 The current work was supported by the Natural Sciences and Engineering Research
6 Council of Canada (NSERC) discovery grant (to CAG), the Veterinary diagnostic service of the
7 Faculty of Veterinary Medicine, University of Montreal and the Animal Pathology Expertise
8 Laboratory of Quebec's Ministry of Agriculture Fisheries and Food (MAPAQ). The authors are
9 grateful to Dr Dale L. Godson (Prairie Diagnostic Services Inc.) for his help with the
10 immunohistochemistry and EM assays. In addition, the authors are grateful to Cynthia M.
11 Guilbert and Sanela Music for critically reviewing the manuscript. The authors are grateful to
12 Ossama Allam, Guy Fontaine and Denis St-Martin for their technical support.

13

14

Sources and manufacturers

- 15 a. Direction du laboratoire d'expertises en analyses alimentaires (DLEAA), Ste-Foy, Québec,
16 Canada.
- 17 b. Laboratoire d'expertise en pathologie animale du Québec (LEPAQ), Québec, Québec,
18 Canada.
- 19 c. Dr D.L. Godson, Prairie Diagnostic Services Inc., Saskatoon, Saskatchewan, Canada.
- 20 d. Dr D.B. Ziola, University of Saskatchewan, Saskatoon, Saskatchewan, Canada.
- 21 e. Lee Biomolecular Research, San Diego, CA, USA.
- 22 f. Dr S. Dea, Institut national de la recherche scientifique – Institut Armand-Frappier, Laval,
23 Québec, Canada.

- 1 g. NBL-7, ATCC CCL 64, American Type Culture Collection, Manassas, VA, USA.
- 2 h. Canadian Food Inspection Agency, Nepean, Ontario, Canada.
- 3 i. QIAGEN Inc., Mississauga, Ontario, Canada.
- 4 j. Sequencing Laboratory, Faculté de médecine vétérinaire, Université de Montréal, St-
5 Hyacinthe, Québec, Canada.
- 6 k. BioEdit Sequence Alignment Editor software version 7.0.5.2, Ibis Therapeutics; Carlsbad,
7 CA, USA.

9 **References**

- 10 1. Banks M, King DP, Daniells C, et al.: 2002, Partial characterization of a novel
11 gammaherpesvirus isolated from a European badger (*Meles meles*). *J Gen Virol* 83:1325-
12 1330.
- 13 2. Fayram SL, Aarnaes SL, Peterson EM, de la Maza LM: 1986, Evaluation of five cell types for
14 the isolation of *Herpes simplex virus*. *Diagn Microbiol Infect Dis* 5:127-133.
- 15 3. Gagnon CA, Allam O, Drolet R, Tremblay D: 2010, Detection of *Bovine lymphotropic*
16 *herpesvirus* DNA in tissues of a bovine aborted fetus. *Can Vet J* 51:1021-1022.
- 17 4. Gagnon CA, Spearman G, Hamel A, et al.: 2009, Characterization of a Canadian mink H3N2
18 *Influenza A virus* isolate genetically related to triple reassortant *Swine influenza virus*. *J*
19 *Clin Microbiol* 47:796-799.
- 20 5. Hargis AM, Ginn PE: 1999, *Feline herpesvirus 1*-associated facial and nasal dermatitis and
21 stomatitis in domestic cats. *Vet Clin North Am Small Anim Pract* 29:1281-1290.

- 1 6. Murphy FA, Gibbs EAJ, Horzinek MC, Studdert MJ: 1999, *Herpesviridae*. In: Veterinary
2 virology, ed. Murphy FA, Gibbs EAJ, Horzinek MC, Studdert MJ, 3th ed., pp. 301-325.
3 Academic Press, San Diego, CA.
- 4 7. Onyekaba C, Bueon L, King P, et al.: 1987, Susceptibility of various cell culture systems to
5 pseudorabies virus. *Comp Immunol Microbiol Infect Dis* 10:163-166.
- 6 8. Onyekaba C, Fahrman J, Bueon L, et al.: 1987, Comparison of five cell lines for the
7 propagation of bovine viral diarrhea and infectious bovine rhinotracheitis viruses.
8 *Microbiologica* 10:311-315.
- 9 9. Pesavento PA, MacLahlan NJ, Dillard-Telm L, et al.: 2004, Pathologic,
10 immunohistochemical, and electron microscopic findings in naturally occurring virulent
11 systemic feline calicivirus infections in cats. *Vet Pathol* 41:257-263.
- 12 10. Powell RA: 1993, Food Habits. In: *The fisher: Life history, ecology, and behavior*, ed.
13 Powell RA, 2nd ed., pp. 105-122. University of Minnesota Press., Minneapolis, MN.
- 14 11. Powell RA, Buskirk SW, Zielinski WJ: 2003, Fisher and marten: *Martes pennanti* and
15 *Martes americana*. In: *Wild mammals of North America: Biology, management, and*
16 *conservation*, eds. Feldhamer GA, Thompson BC, Chapman JA, 2e ed., pp. 635-649. The
17 Johns Hopkins University Press, Baltimore, MD.
- 18 12. Rebell G, Rywlin A, Haines H: 1975, A herpesvirus-type agent associated with skin lesions
19 of green sea turtles in aquaculture. *Am J Vet Res* 36:1221-1224.
- 20 13. VanDevanter DR, Warrener P, Bennett L, et al.: 1996, Detection and analysis of diverse
21 herpesviral species by consensus primer PCR. *J Clin Microbiol* 34:1666-1671.
- 22 14. Willson MF: 1993, Mammals as seed-dispersal mutualists in North America. *Oikos* 67:159-
23 176.

1 15. Wozencraft WC: 2005. Order *Carnivora*. In: Mammal species of the world: a taxonomic and
2 geographic reference, ed. Willson MF, Reeder DM, pp. 532-628. The Johns Hopkins
3 University Press, Baltimore, MD.

4

5 **Figure legends**

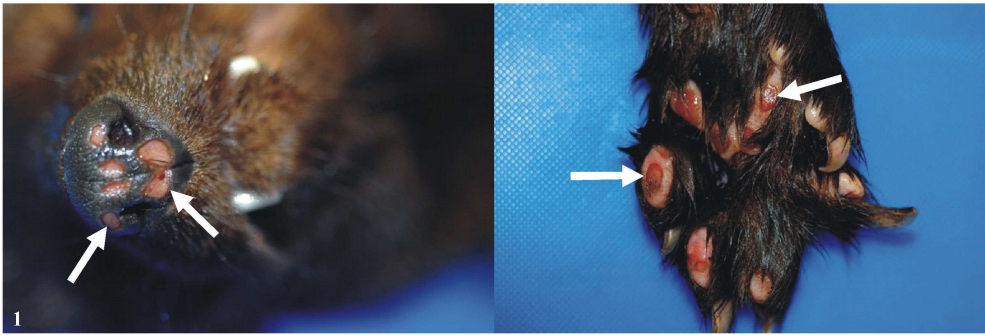
6 **Figure 1.** Fisher skin: palmar pads and muzzle ulcer lesions. Enlarged ulcerative lesions of the
7 muzzle can be seen in the left panel and enlarged ulcerative lesions of one foot pad are illustrated
8 in the right panel. Arrows indicate the ulcers. Scale bars equal 500 and 100 μm , for panel A and
9 B, respectively, and equal 30 μm for panel C and D.

10 **Figure 2.** Fisher skin: representative microscopic findings associated with the ulcer lesions. A)
11 The margin between healthy skin (on the left) and the ulcer lesion (on the right) is indicated by a
12 triangle. B) Koilocytes, with increased perinuclear vacuolation of the cells near an ulcer lesion is
13 indicated by an arrow. C) Enlargement of panel B where koilocyte vacuolation is illustrated. In
14 addition, an arrow indicates a basophilic pseudoinclusion body within the nuclei with a rim of
15 chromatin. D) Localization of large pale amphophilic inclusions filling the nuclei within
16 keratinocytes is indicated by an arrow.

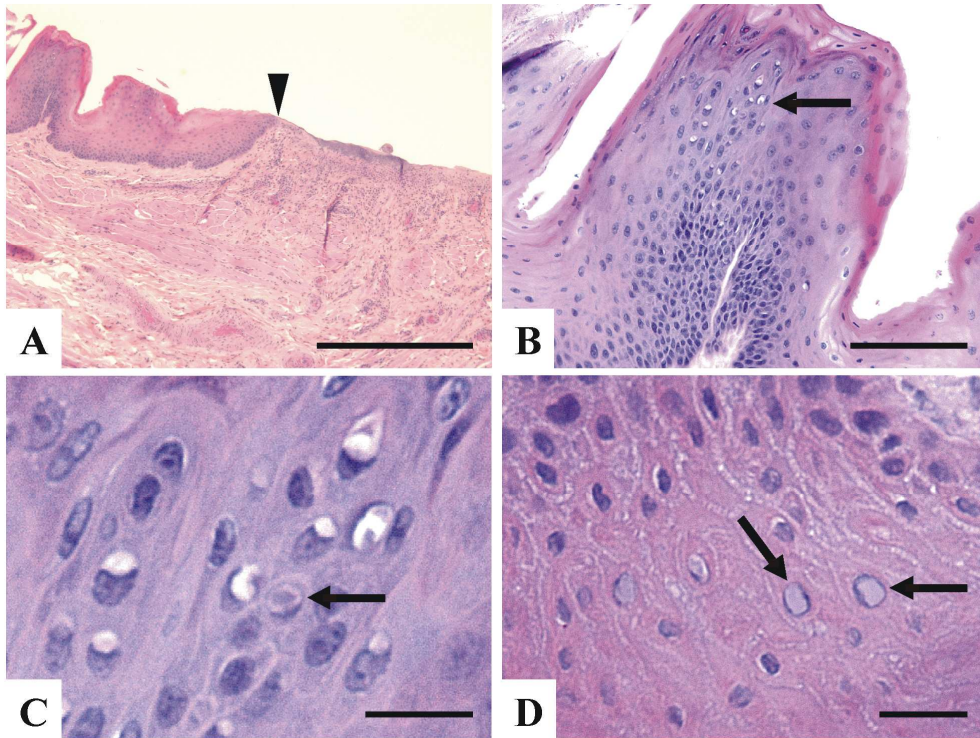
17 **Figure 3.** Partial nucleotides and deduced amino acids sequences of the *Fisher herpesvirus*
18 (FiHV) viral DNA polymerase (DPOL) gene compared to the *Badger herpesvirus* (BadHV)
19 sequences. A) Nucleotides (nt) comparison of the FiHV (GenBank accession number
20 HM579931) to the previously reported BadHV (GenBank accession number AF376034) nt
21 sequence. B) Deduced amino acids comparison of the nt sequences illustrated in panel A.
22 Numbers at the top of the nt sequences are nt positions based on the BadHV sequence

- 1 HM579931. Underlined nt are silent mutations and bold nt are non silent mutations of the viral
- 2 DPOL gene of FiHV compared to BadHV.

For Peer Review



For Peer Review



Review

A)

```

BadHV 5' - TGTAATGCAGTCTATGGATTACAGGTGTGTCCTCGGGTATTTTACCATGCTTGAAAATAGCAGAACTATAAC -3'
FiHV 5' - .....C.T.G..G.....G..C..G..G.....T..T.....C..... -3'

BadHV 5' - 4941 ATATGAAGGGCGACGCATGTTGGAGAAGTCCAAAAATTTATAGAAAACATTACTCCTGTTGAACTCGAAAGAA -3'
FiHV 5' - .....G.....A.....T.....C..C.....C..G..G.....G..... -3'

BadHV 5' - 5015 TTATACACAAACCAATAAATTGTGCATATGATGCTAACTTTAGGGTCATTTATGGTGACACAGACTCTCTT -3'
FiHV 5' - .....A..C.....C..GT.....T..A..C..A.....G.....G..G -3'

```

B)

```

BadHV N- CNAVYGFTGVSSGILPCLKIAETITYEGRRLMLESKNFIENITPVELERIIHKPINCAYDANFRVIYGDTDSL -C
FiHV N- ..S.....T.....TH..S.....V -C

```

64x27mm (600 x 600 DPI)

Peer Review